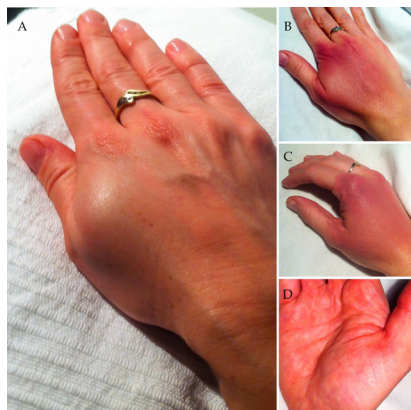

## Arterial injury at LI4

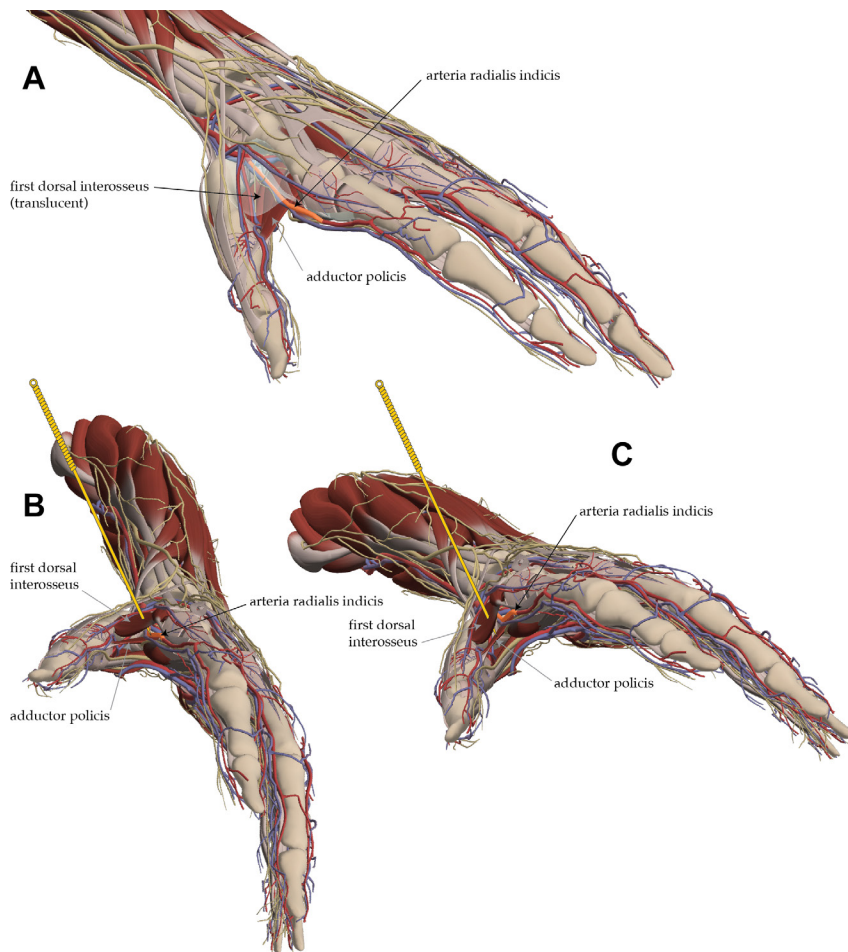
Vascular injuries associated with acupuncture are rare. White reported 12 cases of trauma to blood vessels in his review in 2004,<sup>1</sup> and Witt *et al*<sup>2</sup> reported five events in the category 'lesion of blood vessel' in a prospective study of 2.2 million treatment sessions on 229 230 patients.

This paper reports an arterial injury sustained by a health professional on the first day of a foundation course in Western medical acupuncture, resulting from the first needle insertion at a very common acupuncture point site—LI4. This is the first case of its kind that the author (MC) has seen in 20 years of teaching for the British Medical Acupuncture Society (BMAS). It is reported here, and the relevant anatomy and technique discussed, with the intention of reducing the risk of future occurrences.

Arterial injury from needling LI4 has been reported,<sup>3</sup> and in the same paper the distance to the nearest artery at LI4 was measured to be <10 mm in one fifth of a cohort of 20 subjects as part of a prospective MRI study. What is most interesting in the report by Wong and Hobara is the position of the thumb and first web space, which are perpendicular to the plane of the palm of the hand during imaging. The anatomical significance of this will be discussed and illustrated below.



**Figure 1** Haematoma in first webspace approximately 8 hours post-needling (A); bruising apparent 4 days later (B, C); haematoma visible in palm 10 days later (D).



**Figure 2** Position of arteria radialis indicis between the muscle layers of the first web space [A]; angulation of needle insertion in the plane of the palm [B]; safer angulation perpendicular to the plane of the palm [C]. Primal Pictures. All rights reserved. Primal Pictures, an informa business www.primalpictures.com www.anatomy.tv

In this case the needle was placed at the correct surface location, and inserted briskly to a depth of approximately 15–20 mm. The insertion was associated with deep sharp discomfort followed by a feeling of swelling. The health professional performing the needling was already trained in acupuncture, and was experienced at needling this location and seeing the typical reactions of patients. The discomfort and the slight local swelling was considered a normal needling sensation and reaction. Compression of the needling site was recommended. **Figure 1A** shows the appearance of the hand in the evening of the same day, approximately 8 hours after needling. The subsequent bruising was apparent the next day and became more extensive over the next few days (**figure 1B and C**), and a haematoma in the

palm became prominent at about 10 days and was still present 4 weeks post-needling. Capillary return at the tip of the index finger was observed to be sluggish by a colleague 2 days after the event, but the modified Allen test was consistently normal when undertaken, indicating sufficient collateral arterial supply of the hand from the ulnar artery.

We believe that this was an arterial puncture to the radial metacarpal artery running on the palmar aspect of the second metacarpal (highlighted and labelled as arteria radialis indicis in **figure 2**). This appears to be the closest large artery to the correct surface location of LI4. **Figure 2A** illustrates the position of the artery lying between the first dorsal interosseous muscle (translucent in image) and the adductor pollicis on the radial aspect of the second metacarpal.

Figure 2B and C illustrate how the proximity of a needle tip to the highlighted artery varies with the needle angulation in relation to the plane of the palm of the hand, the safest angulation being closer to perpendicular to the plane of the palm.

The safest angulation for needling the first webspace of the hand can be achieved by placing the hand on a flat surface so that the thumb lies in the same plane as the palm of the hand and needle insertion is perpendicular to this plane.

Mike Cummings,<sup>1</sup> Magdalena Klonowska,<sup>2</sup> Sónia Horta Ferreira<sup>3</sup>

<sup>1</sup>British Medical Acupuncture Society, Royal London Hospital for Integrated Medicine, London, UK

<sup>2</sup>Royal Marsden Hospital Sutton, Sutton, UK

<sup>3</sup>Lisbon, Portugal

**Correspondence to** Dr Mike Cummings, BMAS London, Royal London Hospital for Integrated Medicine, London WC1N 3HR, UK; london@thebmas.com

**Contributors** MC, MK and SHF discussed the case and agreed to write the report. MC drafted the text. MK took the photos, and MC edited and combined

them. MC sourced the anatomy images, created the arrangement and added the needles. MK and SHF read the report and commented. All authors approved the final version of the manuscript accepted for publication.

**Funding** This research received no specific grant from any funding agency in the public, commercial or not-for-profit sectors.

**Competing interests** None declared.

**Provenance and peer review** Not commissioned; internally peer reviewed.

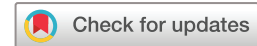

## OPEN ACCESS

**Open Access** This is an Open Access article distributed in accordance with the Creative Commons Attribution Non Commercial (CC BY-NC 4.0) license, which permits others to distribute, remix, adapt, build upon this work non-commercially, and license their derivative works on different terms, provided the original work is properly cited and the use is non-commercial. See: <http://creativecommons.org/licenses/by-nc/4.0/>

© Article author(s) (or their employer(s) unless otherwise stated in the text of

the article) 2018. All rights reserved. No commercial use is permitted unless otherwise expressly granted.



**To cite** Cummings M, Klonowska M, Ferreira SH. *Acupunct Med* Epub ahead of print: [please include Day Month Year]. doi:10.1136/acupmed-2018-011641

Accepted 31 January 2018

*Acupunct Med* 2018;**0**:1–2.  
doi:10.1136/acupmed-2018-011641

## REFERENCES

- White A. A cumulative review of the range and incidence of significant adverse events associated with acupuncture. *Acupunct Med* 2004;22:122–33.
- Witt CM, Pach D, Brinkhaus B, *et al.* Safety of acupuncture: results of a prospective observational study with 229,230 patients and introduction of a medical information and consent form. *Forsch Komplementmed* 2009;16:91–7.
- Wong YM, Hobara H. Hand acupuncture and vascular injury. *J Nippon Med Sch* 2012;79:246–7.