

An alternative approach to pudendal nerve stimulation

Idiopathic chronic pelvic pain and tenesmus are challenging for healthcare providers owing to their unknown aetiology and poor response to treatment.¹ Neuromodulation of pudendal and sacral nerves (S3) with laparoscopically implanted electrodes is an invasive treatment option used for these conditions.² Electroacupuncture (EA) provides a less invasive method of stimulating the pudendal and sacral nerves and has been used for lumbar spinal canal stenosis.³ In our experience EA can also be used to treat chronic pelvic pain and recurrent tenesmus.

The usual approach to pudendal nerve stimulation involves finding the inferior border of the piriformis muscle and needling at an angle towards the midline, avoiding the sciatic nerve (figure 1). This is a difficult approach that is not easily

reproducible and often stimulates the gluteus maximus, resulting in robust gluteal contraction. There is also a concern about the proximity of the inferior gluteal vein and the internal pudendal artery with a theoretical risk of causing deep haematoma.

We felt the need to improve the approach to this nerve owing to the difficulty of the described method and the proximity of deep neurovascular bundles.

A NEW APPROACH

We analysed pelvic anatomy, searching for a different approach that would avoid the gluteus maximus endplate zone and the sciatic nerve, thus consistently and reproducibly improving pudendal nerve stimulation.

We tried an alternative approach needling approximately 1 cm above and medial to the ischial tuberosity at a 45° degree angle towards the median sagittal plane using a 100 mm needle (figure 2). We found that we could stimulate the

pudendal nerve more accurately, and reliably reproduced the technique during every appointment. Our major concern was avoidance of the ramifications of the internal pudendal vein and artery. A study on stress urinary incontinence reported an approach that might stimulate the same target region, needling at BL35.⁴

Three female patients presented to our clinic with chronic pelvic pain and constant tenesmus. After complete gastroenterological and gynaecological investigation, no cause was identified for the symptoms. All patients reported a burning sensation in the rectum, sometimes referred to the vagina. Pain was assessed by Visual Analogue Scale (VAS) score and the Brief Pain Inventory and all patients reported a pain intensity of 8/10 on the VAS. Patients were medicated with gabapentin 200 mg daily, two were taking a serotonin–norepinephrine reuptake inhibitor and one was taking tapentadol 150 mg daily with poor symptomatic control.

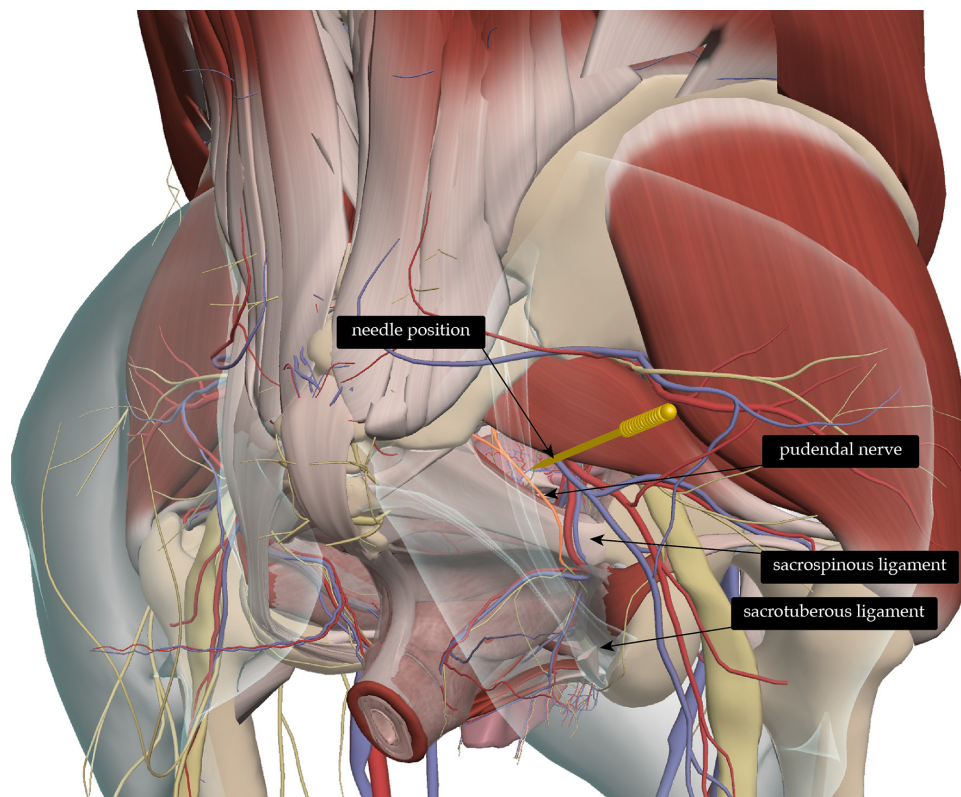


Figure 1 Common pudendal nerve approach. Primal Pictures. All rights reserved. Primal Pictures, a division of Informa, UK. www.primalpictures.com <http://www.anatomy.tv/>

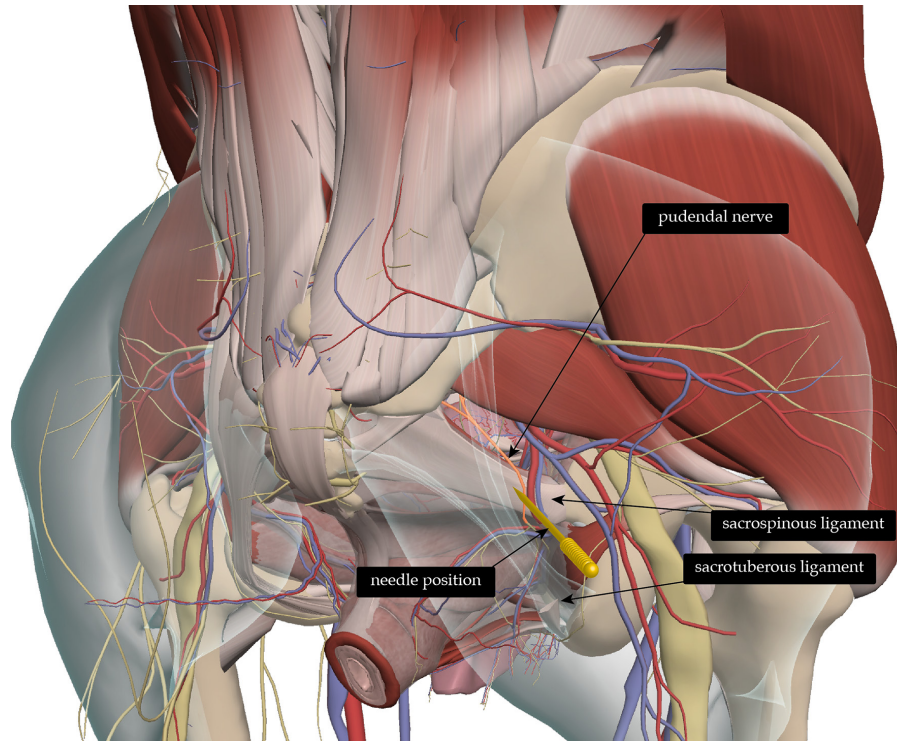


Figure 2 New pudendal approach: the needle is placed 1 cm above and medial to the ischiatic tuberosity, at a 45 degree angle towards the sacrum. Primal Pictures. All rights reserved. Primal Pictures, a division of Informa, UK. www.primalpictures.com <http://www.anatomy.tv/>

We provided weekly treatments for a total of 6 weeks with pudendal nerve stimulation (using the new approach) and sacral nerve stimulation (S2 and S3 levels) bilaterally at 10Hz and 125 μ s for 20 min with an EA stimulator (ITO - ES-160). After this 6-week period, pain was re-evaluated using the VAS: one patient had complete pain relief and two patients reported a reduction in pain intensity to 5/10. In those patients with residual pain after six treatments, another six monthly sessions were performed. After 12 treatments both patients still reported pelvic pain with an intensity of 5/10 on the VAS, but one had no tenesmus. No significant gluteal contractions or haematomas were observed.

Treatment of refractory pelvic pain and tenesmus is challenging. We achieved a pain reduction of at least 3 cm (38%) on the VAS after pudendal and sacral nerve stimulation in patients with refractory symptoms. We believe this technique

may be useful as an adjunct to reduce pelvic pain and tenesmus and needs to be further explored in larger samples.

Mariana Oliveira e Lemos,¹ Mike Cummings²

¹General Practice/Family Medicine, Universidade Nova de Lisboa / Faculdade de Ciências Médicas, Lisboa, Portugal

²British Medical Acupuncture Society, London, UK

Correspondence to Dr Mariana Oliveira e Lemos, General Practice/Family Medicine, Universidade Nova de Lisboa / Faculdade de Ciências Médicas, Lisboa, 1169-056, Portugal; mariana.lemos@me.com

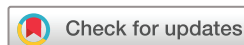Contributors MOeL made the clinical observations and treated the patients. MC suggested publication. MOeL wrote the paper. MC made comments on the text, sourced and edited the diagrams. Both agreed the final text and diagrams.

Competing interests None declared.

Patient consent Obtained.

Provenance and peer review Not commissioned; internally peer reviewed.

© Author(s) (or their employer(s)) 2018. No commercial re-use. See rights and permissions. Published by BMJ.



To cite Oliveira e Lemos M, Cummings M.

Acupunct Med Epub ahead of print: [please include Day Month Year]. doi:10.1136/

acupmed-2018-011751

Accepted 28 June 2018

Acupunct Med 2018;0:1–2.

doi:10.1136/acupmed-2018-011751

REFERENCES

- 1 Mathias SD, Kuppermann M, Liberman RF, *et al.* Chronic pelvic pain: prevalence, health-related quality of life, and economic correlates. *Obstet Gynecol* 1996;87:321–7.
- 2 Li ALK, Marques R, Oliveira A, *et al.* Laparoscopic implantation of electrodes for bilateral neuromodulation of the pudendal nerves and S3 nerve roots for treating pelvic pain and voiding dysfunction. *Int Urogynecol J* 2018;29.
- 3 Inoue M, Hojo T, Nakajima M, *et al.* Pudendal nerve electroacupuncture for lumbar spinal canal stenosis - a case series. *Acupunct Med* 2008; 26:140–4.
- 4 Liu Z, Liu Y, Xu H, *et al.* Effect of electroacupuncture on urinary leakage among women with stress urinary incontinence: a randomized clinical trial. *JAMA* 2017;317:2493.