

# Piriformis Syndrome

Mike Cummings

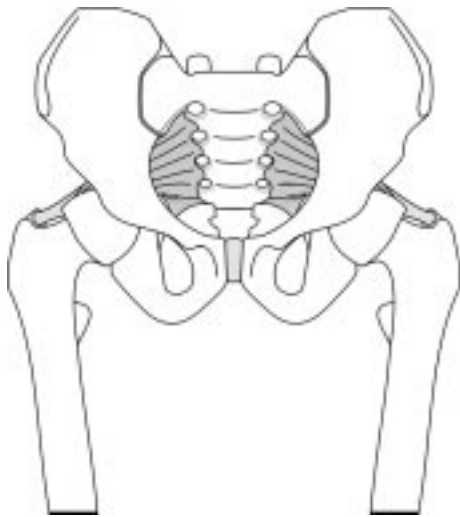
*The following paper is a review of the subject including a retrospective audit of the author's clinical experience of dry needling in lumbogluteal pain.*

The name piriformis is derived from the roots 'pirum' meaning pear and 'forma' meaning shape. It was coined by the Belgian anatomist and botanist Adrian van der Spieghel (also known as Spigelius, 1578 to 1625), professor of anatomy and surgery at Padua.<sup>1,2</sup> The piriformis is not actually a particularly pear-shaped muscle in most people. If its medial attachment is wide, however, and includes the sacrospinous ligament below, and the capsule of the sacroiliac joint above, as well as the anterior surface of the sacrum between the first to fourth foramina, then the muscle is narrowed by the greater sciatic foramen on the way to its lateral attachment on the medial surface of the greater trochanter (see figure 1). In this instance the muscle may bear a somewhat closer resemblance to a pear-shape than is usually the case.

The phylogenetic development of the piriformis in bipedal species apparently derives from the

large, bipennate caudifemoralis muscle, a major muscle of locomotion in lizards.<sup>3</sup>

The piriformis muscle is in close relationship with both the sacroiliac joint and the sciatic nerve. This relationship was first highlighted by Yeoman in his case series on sciatica and radiological findings of the sacroiliac joint, published in the *Lancet* in 1928.<sup>4</sup> In 36% of cases in this series, sciatica was attributed to arthritis of the sacroiliac joint. Yeoman felt that symptoms were due to peri-arthritis involving the anterior sacroiliac ligament, the piriformis muscle, and the adjacent radicals of the sciatic nerve. In 1933 Freiberg & Vinke emphasised the role of the piriformis muscle and its relationship to the sciatic nerve in the aetiology of some cases of sciatica.<sup>5</sup> They speculated that in some resistant cases surgical division of the piriformis tendon may be an appropriate treatment. Four years later Freiberg gave an account of his experience of performing such surgical procedures, and thus the 'piriformis syndrome' is commonly attributed to this author.<sup>6</sup>



*Figure 1. This figure represents an anterior view of the piriformis muscle on both sides. A wide medial attachment to the sacrum is illustrated. The lateral attachment to the upper medial surface of the greater trochanter takes the form of a rounded tendon.*

## Definition

The precise definition of piriformis syndrome is somewhat elusive. The authors to which it is frequently attributed, Yeoman, Freiberg & Vinke, and Freiberg alone, do not mention the term 'piriformis syndrome' in their original papers. They do, however, make reference to concurrent symptoms in a subgroup of patients presenting with sciatica, and draw an association with the piriformis muscle to a greater or lesser extent.<sup>4-6</sup> Robinson (1947) was probably the first to use the term 'piriformis syndrome', and proposed six features to define it.<sup>7</sup> His definition included a history of trauma to the sacroiliac and gluteal regions, so he was probably defining a subgroup of piriformis syndrome, which has since been referred to as 'posttraumatic piriformis syndrome'.<sup>8</sup> Subsequent authors refer either solely to nerve entrapment by the piriformis in the

Table 1

## PREVALENCE OF PIRIFORMIS SYNDROME (PS)

First author	No. in sample	Characteristics of sample	No. with PS	% with PS
Pace <sup>10</sup>	750	Patients admitted and processed through the hospital 'problem back service'	45	6%
Shordania <sup>9</sup>	450	Women attending a polyclinic for lumbago	-	8%
Popelianskii <sup>12</sup>	240	Patients with signs and symptoms of lumbosacral radiculitis	105	44%
Yeoman <sup>4</sup>	100	Patients admitted to hospital for treatment of sciatica	44	44%*
Cummings <sup>†</sup>	123	Patients with lumbogluteal pain, with or without radicular symptoms, presenting to author's clinic	12	10%
Fröhlich <sup>11</sup>	97	Patients presenting with lumbogluteal pain	9	9%
Benson <sup>8</sup>	93	Tertiary referrals from orthopaedic surgeons, patients categorised as having sciatica or hip contusion	14	15%

\* This percentage represents radiological abnormalities of or in the region of the sacroiliac joint, not the clinical presentation of piriformis syndrome.

† Figures from the author's clinic presented in this paper.

area of the greater sciatic foramen, or to a pain syndrome derived from the piriformis muscle, which frequently presents as sciatica.

For the purposes of this text, piriformis syndrome (PS) is defined as a pain syndrome derived from the piriformis muscle, with or without sciatic nerve entrapment. The author acknowledges that other nerves may be entrapped, particularly the superior and inferior gluteal nerves.

### Prevalence

Shordania reported that 8.3% of 450 women attending a polyclinic for lumbago had a hard, swollen, extremely tender piriformis muscle, which he considered responsible for their pain.<sup>9</sup> Pace identified 45 (6%) cases of PS from some 750 patients admitted and processed through the 'Problem Back Service' at Rancho Los Amigos Hospital.<sup>10</sup> He comments that this is likely to be an incomplete series as there was no diagnostic coding for PS, but notes that the incidence of PS is higher than that of confirmed disc protrusion with nerve root deficit in this sample. Fröhlich & Fröhlich found active piriformis trigger points in 20 of 97 patients presenting with lumbogluteal pain.<sup>11</sup> Of these 20, 11 showed signs of additional pathology which was probably primary, leaving 9 (9%) with symptoms solely attributable to PS.

It is likely that Popelianskii & Bobrovnikova's population was different. They found piriformis syndrome in 105 (44%) of 240 patients described as having signs and symptoms of lumbosacral radiculitis.<sup>12</sup> Interestingly, in Yeoman's original series of 100 cases of sciatica admitted to the Royal Bath Hospital, Harrogate, 44 were reported as having an abnormality of the sacroiliac joint,

or in the region of the sacroiliac joint.<sup>4</sup>

Benson & Schutzer performed operative release on 14 cases of PS (15%) from a population of 93 patients, with sciatica or hip contusion, referred by orthopaedic surgeons.<sup>8</sup>

In the author's series of 123 patients treated with acupuncture for lumbogluteal pain, with or without radicular symptoms, 12 (10%) were found to have PS. Five of the 12 had signs of nerve irritation, presumably related to entrapment by piriformis. Table 1 lists data on the frequency of PS from published case series.

PS is said to occur more commonly in women. The often quoted sex ratio of 6:1 is derived from Pace & Nagle's series published in 1976. Fishman L M & Zybert's series of 34 patients recruited for electrophysiological studies also showed a female predominance of 6:1. The series of 26 reported by Durrani & Winnie, however, shows a slight male preponderance (1.4:1),<sup>13</sup> as does the smaller series of Fishman S M et al (8 male, 3 female; ratio 2.7:1).<sup>14</sup> The author's series demonstrates a female to male ratio of 5:1 (10 female, 2 male), consistent with the two largest published reports. Table 2 summarises the limited

Table 2

## SEX RATIO OF PIRIFORMIS SYNDROME (PS)

First author	No. with PS	Female	Male	Ratio F:M
Pace <sup>10</sup>	45	39	6	6:1
Fishman L M <sup>15</sup>	34	29	5	6:1
Durrani <sup>13</sup>	26	11	15	1:1.4
Benson <sup>8</sup>	14	9	5	1.8:1
Cummings <sup>†</sup>	12	10	2	5:1
Fishman S M <sup>14</sup>	11	3	8	1:2.7

† Figures from the author's clinic.

evidence from published literature describing the relative prevalence of PS in women and men.

### **Aetiology**

Piriformis syndrome manifests as myofascial pain derived from the muscle itself, or as nerve entrapment syndrome, or both (see figure 2). Hence the term 'Double Devil' used in 'The Trigger Point Manual'.<sup>1</sup> In the second edition of volume one of the latter, Simons lists acute overload, overwork fatigue, radiculopathy and gross trauma as direct stimuli which can result in activation of myofascial trigger points (TrPs) in skeletal muscle.<sup>16</sup> Piriformis can be overloaded or fatigued by a variety of weight-bearing activities, usually involving some rotation of the hip.<sup>1:10:17:18</sup> Blunt trauma to the buttock is also frequently cited.<sup>8:17-19</sup> Activation of TrPs in piriformis has been documented following car accidents, particularly after a driver's side impact.<sup>20</sup> Such activation may also occur as a result of prolonged maintenance of a position in which the muscle is shortened, for example, the dorsal lithotomy position. Cases of PS have been attributed to this type of position.<sup>17:18</sup> Dysfunction of the sacroiliac joint has been considered as a common component of PS.<sup>17:21:22</sup> Travel and Simons suggest that TrPs in piriformis may be perpetuated by sacroiliac joint dysfunction, and may play a part in sustaining that dysfunction, so that in these circumstances both conditions must be corrected.<sup>1</sup>

The second 'Devil' is nerve entrapment by the piriformis in the area of the greater sciatic foramen. The anatomical arrangements in this area have been studied extensively. Akita et al have studied the innervation of piriformis and glutei medius and minimus.<sup>23-25</sup> Based on the detailed findings of the innervation of the three muscles, they concluded that the muscle fibres of piriformis are chiefly composed of the caudal element of the gluteus medius muscle (89.8%) and in some cases the caudal element of the gluteus minimus muscle as well (10.2%).<sup>24</sup> The peroneal part of the sciatic nerve lies in the tissue plain superficial to gluteus minimus, and the tibial part of the sciatic nerve lies deep to this tissue plain, so when a portion of piriformis is formed by the gluteus minimus muscle layer, it divides the sciatic nerve. This finding is consistent with the largest of the anatomical studies of the relationship between piriformis and the sciatic nerve, in which the peroneal part of the sciatic nerve pierces the body of the muscle in 9.8 to 12.2% of cadavers (see table 3).<sup>26:27</sup> This apparent consistency in stratification between muscle

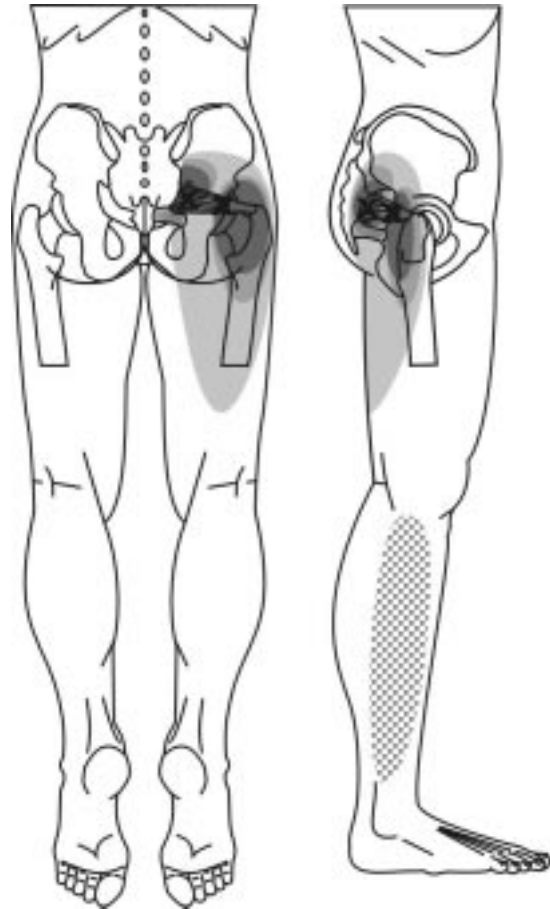


Figure 2. Two TrP sites in the piriformis muscle with the typical pain referral patterns. This figure also illustrates one possible variation of nerve entrapment with paraesthesia on the lateral aspect of the lower limb. The latter would be consistent with irritation of the peroneal division of the sciatic nerve. This diagram is taken from a chapter on myofascial pain in the forthcoming book 'Soft Tissue Rheumatology' (with permission of Oxford University Press).

layers and the nerves of the pelvic outlet is not as clear in some of the smaller anatomical studies.<sup>28-30</sup> The variation could be put down to the small sample sizes in two of the reports,<sup>29:30</sup> but this would not explain Chiba's findings.<sup>28</sup> Perhaps the difference is a true reflection of anatomical variations between different races, although some of the variance may be put down to the more detailed recording of up to 13 anatomical variations in the latter study.<sup>27</sup> Figure 3 illustrates the anatomical variants in the relationship between the piriformis muscle and the sciatic nerve.

Whilst the frequency of the PS (noted in table 1) for patients presenting with lumbogluteal or back pain corresponds with the observed frequency with which the peroneal part of the sciatic nerve

Table 3

Author	Both below	Peroneal through tibial below	Peroneal above tibial below	Both through	Both above	Peroneal above tibial through	Number of limbs
<b>Percentages</b>							
Agur [Grant's] <sup>27</sup>	87.3	12.2	0.5	0	0	0	640
Beaton & Anson <sup>31</sup>	90.0	7.1	2.1	0.8	0	0	240
Beaton & Anson <sup>26</sup>	89.3	9.8	0.7	0.2	0	0	2250
Chiba <sup>28</sup>	60.2	34	1.1*	0.6*	2	1	514
Lee & Tsai <sup>29</sup>	70.2	19.6	1.5	1.8	3	1.2	168
Pecina <sup>30</sup>	78.5	20.7	0.8	0	0	0	130
<b>Absolute numbers calculated from percentages</b>							
Agur [Grant's] <sup>27</sup>	559	78	3	0	0	0	640
Beaton & Anson <sup>31</sup>	216	17	5	2	0	0	240
Beaton & Anson <sup>26</sup>	2009	221	16	5	0	0	2250
Chiba <sup>28</sup>	309	175	6	3	10	5	508
Lee & Tsai <sup>29</sup>	118	33	3	3	5	2	163
Pecina <sup>30</sup>	102	27	1	0	0	0	130
<b>Total numbers and percentages overall</b>							
Total	3313	550	33	12	15	7	3932
<b>Percentage</b>	<b>84.3</b>	<b>14.0</b>	<b>0.8</b>	<b>0.3</b>	<b>0.4</b>	<b>0.2</b>	

\* These figures were estimated from the average of the other samples listed, as precise figures were not available.

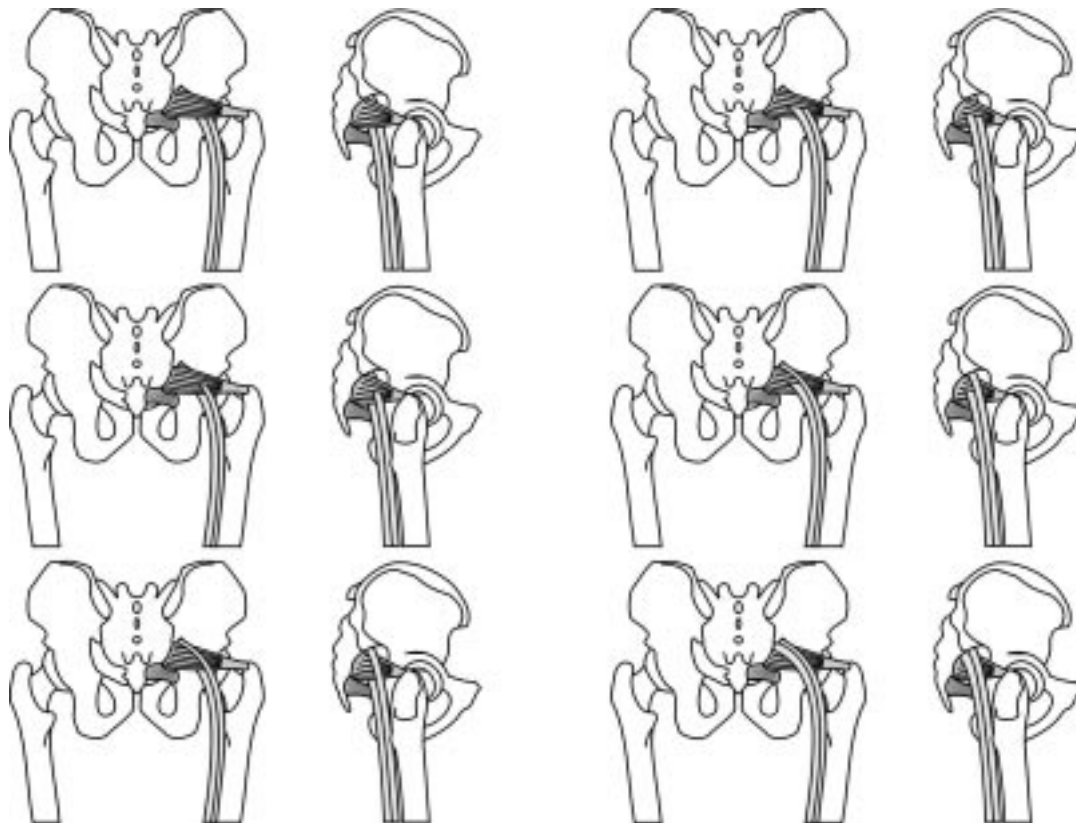


Figure 3. The six reported anatomical variants in the relationship of the two divisions of the sciatic nerve and the piriformis. The top left diagram shows the usual pattern with both divisions passing anterior to the muscle. The middle left diagram shows the peroneal division piercing the muscle (this occurs in about 10% of cases). The remaining four anatomical variants are uncommon, making up no more than about 2% of cases.

pierces the piriformis muscle (about 10%), it is clear that clinically apparent nerve entrapment in PS is not always associated with this anatomical variation. Indeed, Travell & Simons reviewed the published reports of surgical release of the piriformis up to 1988, and they found no descriptions of anatomical variations in the path of the sciatic nerve.<sup>1</sup> Since then there have been case reports of PS resulting from nerve entrapment within piriformis,<sup>32-34</sup> however, these are the minority. In most case reports the entrapment occurs as a result of a mass lesion in or near the greater sciatic foramen. The 'mass' may be hypertrophied piriformis muscle,<sup>8,35</sup> myositis ossificans of the piriformis,<sup>8,36</sup> piriformis pyomyositis,<sup>37-40</sup> haematoma,<sup>41-43</sup> or bursitis.<sup>44</sup> One report describes a clear presentation of PS following a gynaecological procedure in the dorsal lithotomy position. On surgical exploration a pseudoaneurysm of the inferior gluteal artery was found adjacent to the piriformis.<sup>45</sup> Bilateral PS has been reported in association with dystonia musculorum deformans,<sup>46</sup> and several years following bilateral hip arthroplasties.<sup>47</sup> In the latter case, each sciatic nerve was found to be entrapped between a tense piriformis and hypertrophic posterior hip capsule. Superior gluteal nerve entrapment has been described in isolation from other entrapments, and this can cause weakness of the hip adductors as well as buttock pain.<sup>48,49</sup> This is probably one of the rarer causes of a Trendelenburg gait.

The sciatic nerve lesion in PS is thought to be caused by direct pressure from a tight piriformis muscle, however, the situation may be more complicated than this in some cases. Lumbar radiculopathy results in irritability of the peripheral nerve distal to the root lesion. This may result in the sciatic nerve becoming more vulnerable to the pressure from a moderately tight piriformis muscle. This can be referred to as 'double crush'. It is not unusual to see a patient with lumbar radiculopathy develop signs of PS if the piriformis muscle is also tight for some reason. Moreover, tightness in piriformis may result from TrPs activated as a result of the lumbar radiculopathy. The early clinical symptom in radiculopathy or sciatic nerve entrapment by piriformis includes tingling and numbness rather than pain since large diameter fibres (type Ia, Ib / A $\delta$  – proprioceptive; type II / A $\delta$  – light touch) are more vulnerable to pressure than small diameter fibres (type IV / C – nociceptive fibres). In contrast, the early symptom of TrPs is pain rather than tingling since the pain due to TrPs is

peripheral or central sensitisation of nociceptive pathways (Hong 2000, personal communication).

### Diagnosis

The diagnosis of PS is usually based on the findings of clinical examination, and some degree of confirmation is attributed to successful treatment targeted at the piriformis muscle. Clinical tests are aimed at assessing sciatic nerve tension or irritability of piriformis. This author acknowledges that other tests for piriformis syndrome are described in relation to sacral and sacroiliac joint movement, but these are somewhat esoteric and are not referred to in the majority of the literature on PS.

### Sciatic Tension Tests

#### SLR (Figure 4)

The author is surprised that of all the tests that exist in the literature for sciatic tension the straight leg raising should be the one that has been universally adopted in medical schools. It is true that on the rare occasion that the patient with lumbogluteal pain actually has a nerve root impingement from a prolapsed disc, the SLR is generally considerably reduced. In the majority of cases, however, the SLR is of limited value. The reason for this is that when the leg is raised beyond 30 to 50 degrees, not only is the sciatic nerve stretched, but the hamstrings are tightened, rotating the pelvis and flattening the lumbar lordosis. Thus, when the patient experiences pain, it is difficult to be certain about whether the pain has been generated from sciatic tension,



Figure 4. Straight leg raising (SLR). This is primarily a test of sciatic nerve irritation, and is useful if it mimics the patient's symptoms at a relatively low angle (<45 degrees). Above 45 degrees (varies between individuals) the hamstrings tighten and exert a pull on the ischial attachment and sacrotuberous ligament. The result is a rotation of the pelvis and lumbar flexion.

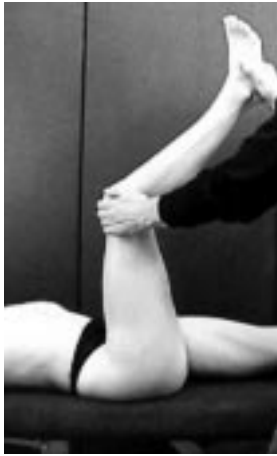

Figure 5. Lasegue's Sign. The hip is flexed to about 90 degrees with the knee flexed. The knee is then extended. This sign is said to be positive if it produces pain in the sciatic notch. This test of sciatic irritation is slightly more discriminatory than the SLR because greater tension is put on the sciatic nerve before significant pelvic and lumbar movement are initiated through tension in the hamstrings.

pelvic or sacroiliac movement, or flexion of the lumbar spine.

#### Lasegue's Sign (Figure 5)

This is a slightly superior manoeuvre, in that the sciatic nerve is put under greater tension, before the hamstrings are tightened and confound the result. With the patient supine, the thigh is flexed to 90 degrees and the knee is allowed to flex to the same degree. The knee is gradually extended until the patient complains of pain or full extension is achieved. This is the equivalent to the manoeuvre performed when the patient is asked to extend his or her leg from the sitting position.

The limitations of both SLR and Lasegue's sign in the assessment of sciatic and PS have been noted.<sup>4,6</sup>

#### Bowstring Test (Figure 6)

This is by far the best test of those mentioned for sciatic tension. It involves flexion of the thigh, a variable degree of knee flexion and full dorsiflexion of the foot. In this position a longitudinal cord can be felt in the popliteal fossa. This is the popliteal or posterior tibial nerve. Pressure on this cord applies isolated tension to the sciatic nerve and its roots. The advantage of this test is that the final 'bowstring' manoeuvre is performed with the rest of the body stationary, so that the response produced can be solely attributed to tension in the sciatic nerve, provided, of course, that there is no local pathology in the popliteal fossa.

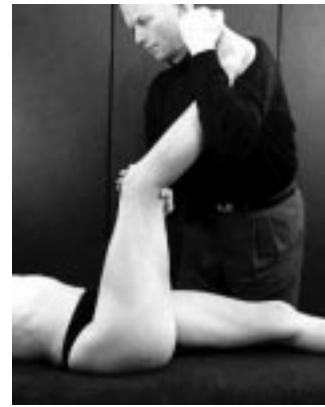

Figure 6. Bowstring Test. In determining sciatic irritation, this manoeuvre is superior to either the SLR or Lasegue's sign. It is performed in hip flexion, a variable degree of knee flexion and full dorsiflexion of the ankle. The examiner maintains a position in which a longitudinal cord (popliteal or tibial nerve) is palpable in the centre of the popliteal fossa. The test involves applying pressure directly to the nerve. Normally this will result in a sensation of nerve tension (mild burning and stretching) at the back of the knee. The test is positive if it produces the patient's lumbogluteal or sciatic pain, or related dysaesthesia.

#### Slump Test<sup>50</sup> (Figure 7)

The slump test is a very sensitive test for sciatic irritation. It is rarely mentioned in the medical literature. In the seated position the patient 'slumps' forward into maximal thoracic and lumbar flexion. Cervical flexion is then added. The patient is asked to attempt to straighten one leg. At each stage the pain response can be noted, and over-pressure can be applied to the



Figure 7. Slump Test. This can be quite a complex test involving a number of different positions (for full description see Maitland).<sup>48</sup> In brief it involves full thoracic and lumbar flexion in the seated position (the slump), then cervical flexion, followed by knee extension and ankle dorsiflexion. Hip flexion is maintained at around 90 degrees, but may be increased in the most supple patients with the subtlest signs of dysfunction. This can be used as a sensitive test of sciatic irritation.



Figure 8. Slump with Bowstring. This combination of the Slump test with the Bowstring test was developed by the author to rapidly detect very subtle degrees of sciatic irritation, as may be present in some cases of piriformis syndrome. See full text for details.

movement. The final manoeuvre is to add dorsiflexion of the ankle. Clearly this set of movements can elicit pain from a number of structures, so it must be performed sequentially with assessment at each stage. If the patient's lumbogluteal pain or sciatica is produced by knee extension or dorsiflexion of the ankle, it is likely to result from increased tension in the sciatic nerve or its roots. This is quite a time consuming test to perform fully, and the result could theoretically be confounded by pain from the hamstring muscles.

*Slump with Bowstring* (Figure 8)

The author has devised a modification of the slump test by adding the final manoeuvre of the bowstring test to the end position of the former. This can be performed much more rapidly than the full slump test, and has the advantage of being more sensitive than the standard bowstring test, and more specific for sciatic irritation than the slump test. The slump position is assumed as above, but if at any stage the patient becomes uncomfortable, the degree of spinal flexion can be reduced slightly. The knee is allowed to maintain a variable degree of flexion and the ankle is fully dorsiflexed by resting the forefoot on the examiner's knee. The position should be maintained passively with the patient comfortable. The final bowstring of the popliteal nerve behind the knee will always produce a sensation of nerve tension. It is important to distinguish between this and replication of the patient's pain complaint or other symptom. TrPs in piriformis can produce very subtle degrees of sciatic nerve irritation which can be detected using this test. To the knowledge of the author, this is the first description of such a test in the literature.



Figure 9. Freiberg's Test. Freiberg described limitation of internal rotation of the hip in extension secondary to 'spasm' of piriformis.

*Tests for Piriformis*

This refers to tests which are designed to elicit pain from the piriformis muscle or from associated nerve entrapment by stretching, resisted contraction or pressure applied to the muscle.

*Freiberg's Test* (Figure 9)

This is one of the earliest tests for piriformis reported in the medical literature.<sup>5</sup> The test involves passive internal rotation of the leg with the hip in extension. The original description suggests that the patient lies prone on a firm surface with the hips in extension. The knee is flexed to 90 degrees to facilitate internal rotation of the thigh. This movement stretches the piriformis muscle and may elicit pain in the area of the sciatic notch; however, Frieberg intended this manoeuvre to test for limitation of movement secondary to 'spasm' of piriformis, rather than for it to be used to provoke pain. The test also stretches the other short external rotators of the leg - the gemelli, obturator internus and quadratus femoris.

*Pace Abduction Test*<sup>10:51</sup> (Figure 10)

This is a very valuable and simple test which involves resisted abduction of the thighs in the

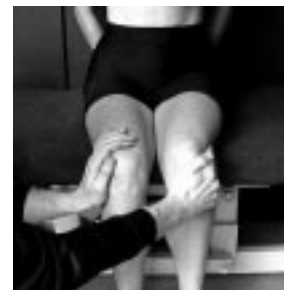

Figure 10. Pace Abduction Test. In this test the examiner resists active abduction of the thighs with the hips flexed in a seated position. As piriformis is the prime mover in this position, this test is likely to provoke pain arising from the muscle, or from nerve entrapment by the muscle.

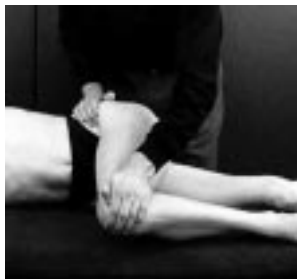

Figure 11. AIF Position. This position is likely to provoke symptoms in PS. AIF stands for abduction, internal rotation and flexion, and refers to movement at the hip.

seated patient. Piriformis is relatively isolated from the other short external rotators in this position of 90 degrees hip flexion. Pain and weakness of abduction constitute a positive test. Unfortunately this test is not always positive in PS.<sup>13</sup>

*AIF Position* (Figure 11)

The AIF position is said to exacerbate the pain and any nerve entrapment associated with PS.<sup>15:22</sup> The acronym stands for **a**dduction, **i**nternal rotation and **f**lexion, and refers to the hip of the side being tested. With the patient side-lying on the unaffected side, the uppermost hip is flexed to about 60 degrees and the knee allowed to rest on the examination couch. With the ankle of the top leg resting on the lower knee, the upper hip lies in moderate internal rotation.



Figures 12. Piriformis Stretch. The examiner adducts the flexed hip while retracting the upper ilium to produce an almost isolated stretch of piriformis.

*Piriformis Stretch* (Figures 12 to 14)

The most effective way to achieve an almost isolated stretch of piriformis is to fully adduct the thigh with the hip flexed to 90 degrees. This can be performed with the patient side-lying during a clinical assessment,<sup>52</sup> or can be performed by the supine patient as a self-stretch manoeuvre as part of the treatment for PS.<sup>1</sup> A similar position is achieved by simply crossing one leg fully over the other in a seated position.

*Beatty's Test*<sup>53</sup> (Figure 15)

This test is performed with the patient side-



Figures 13. Piriformis Self-stretch 1. In the supine position, the patient flexes the hip to 90 degrees and adducts the leg across the opposite hip. In the figure the right piriformis is being stretched. The right hand restrains the ipsilateral ilium to prevent the pelvis lifting, and the left hand guides the movement of the right leg, adding pressure on the lateral aspect of the knee to enhance the stretch. The stretch can be enhanced further by post-isometric relaxation, i.e. the left hand resists an isometric contraction of the right piriformis (attempted abduction of the right thigh) for a few seconds, after which the muscle is relaxed and stretched a little further.



Figures 14. Piriformis Self-stretch 2. This manoeuvre is virtually identical to that in figure 10, except that it is performed in the seated position.

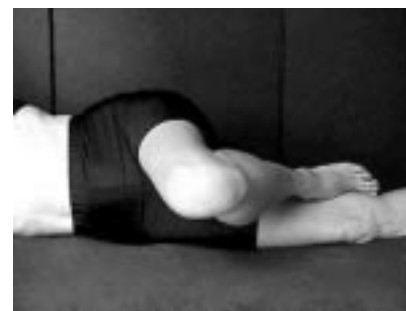

Figure 15. Beatty's test. In the side-lying position, with the top leg flexed at the hip and knee, the patient is asked to lift the flexed knee up a few inches and hold it in position. Patients with PS are likely to develop deep gluteal pain in this position. The test is not dissimilar in effect from Pace's abduction test.

lying and the upper thigh flexed to 90 degrees. The patient is asked to lift the knee of the top leg a few inches off the couch and hold it there. This



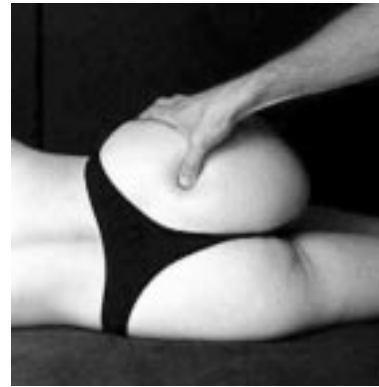Figure 16. Modification of Beatty's test. In patients with more subtle clinical presentations the author modifies Beatty's test by adding resistance in various degrees of abduction. In this way, the bulk and tension of piriformis is altered in the greater sciatic foramen. This test is considered positive by the author if the patient's symptoms of nerve entrapment are mimicked or their deep gluteal pain is produced.

test is positive if it reproduces deep buttock pain. The author uses a similar technique routinely in the assessment of PS, adding resistance at various degrees of abduction (see figure 16). In this way, the bulk and tension of piriformis is altered in the greater sciatic foramen. This test is considered positive if the patient's symptoms are mimicked.

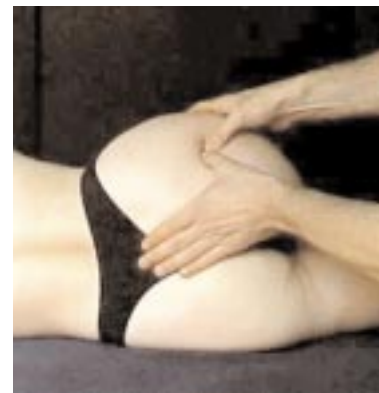*Palpation of Piriformis* (Figures 17 & 18)

Piriformis can be palpated through gluteus maximus as a thick band deep in the gluteal region with the patient side-lying and the upper hip flexed to 90 degrees. The band is most easily palpated at about one third of the distance from the greater trochanter to the sciatic notch. This point is often tender, and it corresponds with the acupuncture point GB30, found one third of the way along a line from the highest point of the greater trochanter to the sacral hiatus. Tenderness in piriformis can also be elicited in the sciatic notch, although it is not possible to detect a band of tissue at this site. The patient should be asked whether they recognise the pain produced by deep palpation at these sites, i.e. is their pain reproduced by palpation?

The only way to directly palpate piriformis is on rectal or vaginal examination. The body of the muscle proximal to the greater sciatic foramen, and its attachment to the sacrum, can be palpated above the iliac spine and sacrospinous ligament. This may be one of the most reliable tests for PS,<sup>10;13;51;54;55</sup> and it should certainly be part of a comprehensive assessment of the patient with low back pain or sciatica,<sup>10</sup> being the only method of detecting intrapelvic masses on clinical examination. It should be noted,



Figures 17. Palpation of Piriformis. The extra-pelvic portion of piriformis can be palpated through gluteus maximus between the sciatic notch and the greater trochanter. The best position for the patient to be in is side-lying with the upper leg flexed to 90 degrees at the hip and the knee. This figure illustrates pressure applied in the sciatic notch. The pressure on piriformis can be increased in this position by contraction of the muscle, i.e. by asking the patient to abduct the flexed (upper) thigh slightly.



Figures 18. Palpation of Piriformis. In the same position as figure 14, the lateral portion of piriformis can be palpated as a deep band of tissue stretching from the sciatic notch towards the greater tuberosity. It can only be felt by deep palpation across the line of the fibres.

however, that a clinician with short fingers will be unlikely to reach the piriformis muscle in a large framed patient.

*Special Investigations*

Fishman et al demonstrated a delay in the modified Hoffman reflex (an electrophysiological equivalent of the ankle jerk) in patients with PS.<sup>15</sup> They also correlated the latency with the angle of internal rotation in the AIF position. Unfortunately an independent team has not been able to replicate this finding.<sup>56</sup> Somatosensory evoked potentials (SEPs) have been used to determine a peripheral nerve conduction deficit in PS,<sup>57;58</sup> however, SEPs

would not easily distinguish between nerve compression at the pelvic outlet and root compression. In one case report of PS, isotope scanning appeared to aid the diagnosis,<sup>59</sup> but this investigation does not seem to have caught on. As always there is considerable interest in the use of CT and MR imaging techniques. A number have authors have suggested their potential use in investigating the pelvic outlet and in PS.<sup>60-64</sup> Such imaging is clearly valuable in identifying abnormal pathology,<sup>64</sup> and indeed unilateral piriformis hypertrophy can be determined;<sup>8,62</sup> unfortunately, the latter does not necessarily correlate with the symptomatic side.<sup>8</sup>

In conclusion, PS remains a clinical diagnosis. The diagnosis is sometimes supported by special investigations, but most often its confirmation is suggested by resolution of symptoms following therapy targeted at the offending piriformis muscle.

### **Treatment**

Treatments which have been reported as successful for PS vary from non-invasive physical modalities, through the minimally invasive needling and injection techniques, to invasive surgical procedures.

#### *Non-invasive Treatments*

##### *Stretch*

Stretch, with or without the use of vapocoolant sprays has been reported as a successful treatment for PS.<sup>1,22,61,65-68</sup> Figure 12 illustrates an efficient stretch of piriformis performed by the physician or therapist. Self-stretch techniques can be taught to the patient for use at home. Figures 13 & 14 are illustrative of suitable self-stretch techniques. Stretch of skeletal muscle can be



*Figures 19. This figure shows a 75mm acupuncture needle in the lateral trigger point area of piriformis, which corresponds closely to the acupuncture point GB30. In this position piriformis is on stretch, so that during needle insertion an increase in resistance can be detected as the needle tip enters this muscle.*

enhanced following isometric contraction – i.e. post-isometric relaxation,<sup>69</sup> and this technique can also be taught to the patient for use at home.

##### *Pressure*

Pressure can be applied with the thumbs as illustrated in figures 17 & 18.<sup>1</sup> Firm pressure can constitute 'ischaemic compression', as described by Travell & Simons,<sup>70</sup> although Simons now favours a lighter application of pressure, termed 'pressure release'.<sup>16</sup> Osteopaths seem to prefer the elbow for application of pressure to piriformis,<sup>17,68</sup> but care should be taken to avoid unnecessary application of pressure to the sciatic nerve using this technique.<sup>1</sup> The effectiveness of these procedures is likely to be enhanced if the muscle is placed on moderate stretch.<sup>1</sup>

##### *Massage*

Massage of the intrapelvic portion of piriformis has been described.<sup>71</sup> This technique requires deep insertion of the physician's finger per rectum to allow stroking massage along the length of the piriformis fibres. This method of treatment does not appear to have become popular in the UK, although the author suspects it may be practised on the continent.

##### *Other Modalities*

The use of ultrasound in PS is described,<sup>61,72</sup> as is the application of shortwave diathermy.<sup>1,73</sup> Other forms of electrotherapy have been found useful in the treatment of myofascial trigger points,<sup>74-76</sup> as has low level laser therapy,<sup>77,78</sup> however, these therapies do not appear to have been specifically tested on trigger points in piriformis.

#### *Needling & Injection Techniques*

##### *Dry Needling (Acupuncture)*

This paper constitutes, to the author's knowledge, the first report of the use of acupuncture in the treatment of PS. In this series 9 cases of PS responded satisfactorily to simple dry needling of TrPs. One case, resistant to a course of dry needling, was successfully treated with a deep steroid injection aimed at a TrP in the lateral portion of the right piriformis. Two patients failed to attend after their initial assessment. In most cases treatment consisted of brief dry needling of TrPs with a 75 mm acupuncture needle in piriformis. The position adopted for needling is that which puts piriformis on stretch (figure 12). The needle is inserted over the site of maximum tenderness and advanced until the increased resistance of the stretched muscle is reached or the patient recognises their pain. Figure 19 shows a 75 mm needle inserted into the lateral portion of piriformis. When aiming for the

most medial portion of piriformis accessible externally an additional needle can be inserted as a guide of depth onto the sacrum at the medial border of the sciatic notch. Direct needling of the sciatic nerve should be avoided; however, the atraumatic tips of acupuncture needles are much less likely to cause nerve damage than the cutting edge of a bevelled needle, or indeed, an injection of fluid directly into the nerve.

Table 4 summarises the results of acupuncture treatment for lumbogluteal pain in the author's clinic from 1993 to 1998. Details are given of the varying success in the different sub-categories. PS was not used as a sub-category in the author's database of results. Information of PS was extracted by a search of the 'diagnosis' field of the database, so patients with PS are also included within one of the other sub-categories.

*Injection*

Local anaesthetic and steroid is the most popular combination for injection into piriformis,<sup>10,55,61,79,80</sup> although local anaesthetic alone is used first-line by some clinicians.<sup>1,10,48</sup> One study describes injection of radiopaque contrast media,<sup>14</sup> and another compares steroid with botulinum toxin A.<sup>81-83</sup> Most authors comment on the empirical efficacy of injection techniques; however, it should be noted that an effect beyond placebo has not been established for any needling therapy in myofascial pain.<sup>84</sup>

As there is an inherent risk of damage to the sciatic nerve from virtually any injection

technique in the gluteal region, but particularly from deep injection in the area of the sciatic notch, clinicians have described special techniques for ensuring the positioning of the needle in piriformis. Pace describes injecting towards the clinicians finger, which is placed onto the inner surface of piriformis per rectum.<sup>10</sup> This finger locates the most tender point in piriformis and can feel when the needle tip disturbs the tissues above the point. Travell and Simons describe a similar bimanual technique for injecting the medial portion of the muscle in the sciatic notch, and their standard external technique for injecting the lateral portion.<sup>1</sup> Durrani found the bimanual technique unnecessarily uncomfortable, and in his series describes a blind technique of 'walking' the needle tip off the edge of the sciatic notch into piriformis.<sup>13</sup> Hanania describes a technique using a special EMG needle.<sup>79,85</sup> The insulated needle is set up to stimulate at its tip. As it is introduced twitching can be seen in gluteus maximus. When piriformis is reached there is a subtle abduction of the hip and a reduction in twitch from gluteus maximus. Beyond piriformis, plantar flexion occurs, as there is direct stimulation of the sciatic nerve. Local anaesthetic and steroid can be injected close to the sciatic nerve and within piriformis as the needle is withdrawn. Fishman also used an insulated EMG needle for injection, and confirmed the position with fluoroscopy.<sup>14</sup> He approached the piriformis more laterally (close to

Table 4

**RETROSPECTIVE REVIEW OF PRESENTATIONS TO AUTHOR'S CLINIC WITH LUMBOGLUTEAL PAIN, 1993 TO 1998**

<i>Sub-category</i>	<i>Total</i>	<i>nfu</i>	<i>TrPs present - no. [%]</i>	<i>Successful outcomes</i>	<i>% Success</i>
<b>Lumbogluteal pain</b>	123	13	87 [71]	76	69
<b>HGP</b>	27	3	25 [93]	22	92
<b>LBP</b>	53	6	31 [58]	36	77
<b>LBPS</b>	31	3	15 [48]	13	46
<b>S</b>	12	1	4 [33]	5	45
<b>PS</b>	12	2	12 [100]	10	100

HGP Hip girdle pain - a sub-category of lumbogluteal pain.

LBP Low back pain - a sub-category of lumbogluteal pain.

LBPS Low back pain with sciatica - a sub-category of lumbogluteal pain.

S Sciatica alone - a sub-category of lumbogluteal pain.

nfu No follow-up after initial assessment.

PS Piriformis syndrome cases are represented across the other categories as it does not have a category in its own right in the author's database. Eight cases were categorised under HGP, one under LBP, one under LBPS, and two under S.

GB30), and confirmed the position prior to injection by getting the patient to contract piriformis while he monitored the EMG activity. Position was confirmed during injection by fluoroscopy. No comment was made about injecting anything other than radiopaque contrast media, and it is not clear whether or not the patients got better.

Porta performed an RCT comparing the efficacy of local anaesthetic and steroid with botulinum toxin A in the treatment of myofascial pain arising from three rather inaccessible muscles – piriformis, iliopsoas and scalenus anterior.<sup>81-83</sup> CT was used to ensure correct placement of needles. Both groups were given a programme of specific stretching exercises in addition to injection. It is surprising that the clinician was not blinded to the injected substance. This would have been a simple process in comparison with the difficulty of the injection procedure as a whole. The groups were different at baseline, and there was a significant intergroup difference in terms of compliance with the stretching exercises. Overall this study does not allow any safe conclusions to be drawn about the relative efficacy of the two injected substances. Moreover, there is already a considerable body of evidence from rigorous RCTs supporting the contention that the efficacy of injection techniques in myofascial pain is independent of the injected substance.<sup>84</sup>

### Surgery

#### *Piriformis release & Sciatic Neurolysis*

The surgical approach to the treatment of PS seems to be frequently reported or referred to in the literature on PS.<sup>6-8;30;32;34;35;47;61;62;72;86-93</sup> Few would disagree that a surgical procedure should be withheld until conservative measures have been exhausted, however, despite many reports of success with conservative treatment,<sup>1;10;18;19;22;51;55;61;66;67;72;73;79-83;94;95</sup> some patients are still submitted to surgery without a trial of needling or injection.<sup>8</sup>

Clearly there are some cases that present as PS which will require surgical exploration,<sup>8;36;41-43;45;47</sup> but most of these will be picked up with modern imaging techniques.<sup>60;64</sup>

### Conclusion

Piriformis syndrome is a pain syndrome derived from the piriformis muscle, with or without sciatic nerve entrapment. It remains a controversial and esoteric clinical diagnosis. This is due to a lack of controlled trials in assessing the

reliability of clinical features and in determining the efficacy of treatments. There are no rigorous estimates of the prevalence of PS, although preliminary data suggests that it occurs in about 9% in patients presenting with lumbogluteal pain. As a subgroup of patients presenting with 'sciatica', this author believes that PS is a worthwhile diagnosis to seek, as the response to dry needling appears to be considerably better than in radiculopathy.

### Acknowledgment

The author would like to thank Professor Hong for his comments on the text of this paper.

**Mike Cummings MB ChB Dip Med Ac**  
 Director of Education BMAS  
 DoE@medical-acupuncture.org.uk

### Reference List

1. Travell JG, Simons DG. Myofascial Pain & Dysfunction. The Trigger Point Manual. Volume 2. The Lower Extremities. Baltimore: Williams & Wilkins, 1992.
2. Firkin BG, Whitworth JA. Dictionary of Medical Eponyms. Carnforth: The Parthenon Publishing Group, 1990.
3. Romer AS, Parsons TS. The Vertebrate Body. Philadelphia: W B Saunders, 1977.
4. Yeoman W. The relation of arthritis of the sacroiliac joint to sciatica. *Lancet* 1928;ii:1119-22.
5. Freiberg AH, Vinke TH. Sciatica and the sacro-iliac joint. *J Bone Joint Surg* 1933;16:1.
6. Freiberg AH. Sciatic pain and its relief by operations on muscle and fascia. *Arch Surg* 1937;34:337-50.
7. Robinson DR. Piriformis syndrome in relation to sciatic pain. *Am J Surg* 1947;73:355-8.
8. Benson ER, Schutzer SF. Posttraumatic piriformis syndrome: diagnosis and results of operative treatment. *J Bone Joint Surg Am* 1999;81:941-9.
9. Shordania JF. Die chronischer Entzündung des Musculus piriformis - die piriformitis - als eine der Ursachen von Kreuzschmerzen bei Frauen. *Die Medizinische Welt* 1936;10:999-1001.
10. Pace JB, Nagle D. Piriform syndrome. *West J Med* 1976;124:435-9.
11. Fröhlich D, Fröhlich R. Piriformis syndrome: A frequent item in the differential diagnosis of lumbogluteal pain. *Manuelle Medizin* 1995;33:7-10.
12. Popelianskii Ialu, Bobrovnikova TI. [The syndrome of the piriformis muscle and lumbar discogenic radiculitis.] (Russian). *Zh Nevropatol Psikiatr* 1968;68:656-62.
13. Durrani Z, Winnie AP. Piriformis muscle syndrome: an underdiagnosed cause of sciatica. *J Pain Symptom Manage* 1991;6:374-9.
14. Fishman SM, Caneris OA, Bandman TB, Audette JF, Borsook D. Injection of the piriformis muscle by fluoroscopic and electromyographic guidance. *Reg Anesth Pain Med* 1998;23:554-9.
15. Fishman LM, Zybert PA. Electrophysiologic evidence of piriformis syndrome. *Arch Phys Med Rehabil* 1992;73:359-64.

16. Simons DG, Travell JG, Simons PT. Travell & Simons' Myofascial Pain & Dysfunction. The Trigger Point Manual. Volume 1. Upper Half of Body. Baltimore: Williams & Wilkins, 1999.
17. Retzlaff EW, Berry AH, Haight AS, Parente PA, Lichty HA, Turner DM *et al.* The piriformis muscle syndrome. *J Am Osteopath Assoc* 1974;73:799-807.
18. Namey TC. Emergency diagnosis and management of sciatica: differentiating the non-diskogenic causes. *Emergency Med Reports* 1985;6:101-9.
19. Brown JA, Braun MA, Namey TC. Piriformis syndrome in a 10-year-old boy as a complication of operation with the patient in the sitting position. *Neurosurgery* 1988;23:117-9.
20. Baker BA. The muscle trigger: evidence of overload injury. *J Neurol Orthop Med Surg* 1986;7:35-44.
21. Kirkaldy-Willis WH, Hill RJ. A more precise diagnosis for low-back pain. *Spine* 1979;4:102-9.
22. Steiner C, Staubs C, Ganon M, Buhlinger C. Piriformis syndrome: pathogenesis, diagnosis, and treatment. *J Am Osteopath Assoc* 1987;87:318-23.
23. Akita K, Sakamoto H, Sato T. Stratificational relationship among the main nerves from the dorsal division of the sacral plexus and the innervation of the piriformis. *Anat Rec* 1992;233:633-42.
24. Akita K, Sakamoto H, Sato T. Arrangement and innervation of the glutei medius and minimus and the piriformis: a morphological analysis. *Anat Rec* 1994;238:125-30.
25. Akita K. A comparative anatomical study of muscles of the pelvic outlet and the piriformis with special reference to their innervation. *Kaibogaku Zasshi* 1997;72:9-12.
26. Beaton LE, Anson BJ. The relation of the sciatic nerve and its subdivisions to the piriformis muscle. *Anat Rec* 1937;70:1-5.
27. Grant's Atlas of Anatomy. Baltimore: Williams & Wilkins, 1991.
28. Chiba S. [Multiple positional relationships of nerves arising from the sacral plexus to the piriformis muscle in humans]. *Kaibogaku Zasshi* 1992;67:691-724.
29. Lee CS, Tsai TL. [The relation of the sciatic nerve to the piriformis muscle]. *Taiwan I Hsueh Hui Tsa Chih* 1974;73:75-80.
30. Pecina M. Contribution to the etiological explanation of the piriformis syndrome. *Acta Anat (Basel)* 1979;105:181-7.
31. Beaton LE, Anson BJ. The sciatic nerve and the piriformis muscle: their interrelationship a possible cause of coccygodynia. *J Bone Joint Surg* 1938;20:686-8.
32. Chen WS. Bipartite piriformis muscle: an unusual cause of sciatic nerve entrapment. *Pain* 1994;58:269-72.
33. Ozaki S, Hamabe T, Muro T. Piriformis syndrome resulting from an anomalous relationship between the sciatic nerve and piriformis muscle. *Orthopedics* 1999;22:771-2.
34. Sayson SC, Ducey JP, Maybrey JB, Wesley RL, Vermillion D. Sciatic entrapment neuropathy associated with an anomalous piriformis muscle. *Pain* 1994;59:149-52.
35. Lam AW, Thompson JF, McCarthy WH. Unilateral piriformis syndrome in a patient with previous melanoma. *Aust NZ J Surg* 1993;63:152-3.
36. Beauchesne RP, Schutzer SF. Myositis ossificans of the piriformis muscle: an unusual cause of piriformis syndrome. A case report. *J Bone Joint Surg Am* 1997;79:906-10.
37. Chen WS. Sciatica due to piriformis pyomyositis. Report of a case. *J Bone Joint Surg Am* 1992;74:1546-8.
38. Chusid MJ, Hill WC, Bevan JA, Sty JR. Proteus pyomyositis of the piriformis muscle in a swimmer. *Clin Infect Dis* 1998;26:194-5.
39. Kinahan AM, Douglas MJ. Piriformis pyomyositis mimicking epidural abscess in a parturient. *Can J Anaesth* 1995;42:240-5.
40. Picco AG, Parajua Pozo JL. [The piriformis muscle syndrome due to pyomyositis]. *Med Clin (Barc.)* 1993;100:436-7.
41. Katati MJ, Vilchez R, Pinar L, Abdulha O, Horcajadas A, Ros B *et al.* Haematoma of the piriformis muscle simulating a giant presacral tumour: unusual case of lumbosacral radiculopathy. *Acta Neurochir.(Wien)* 1998;140:403-4.
42. Ku A, Kern H, Lachman E, Nagler W. Sciatic nerve impingement from piriformis hematoma due to prolonged labor. *Muscle Nerve* 1995;18:789-90.
43. Stevens KJ, Banuls M. Sciatic nerve palsy caused by haematoma from iliac bone graft donor site. *European Spine Journal* 1994;3:291-3.
44. Peh WC, Reinus WR. Piriformis bursitis causing sciatic neuropathy. *Skeletal Radiol* 1995;24:474-6.
45. Papadopoulos SM, McGillicuddy JE, Albers JW. Unusual cause of 'piriformis muscle syndrome'. *Arch Neurol* 1990;47:1144-6.
46. Gandhavadi B. Bilateral piriformis syndrome associated with dystonia musculorum deformans. *Orthopedics* 1990;13:350-1.
47. Uchio Y, Nishikawa U, Ochi M, Shu N, Takata K. Bilateral piriformis syndrome after total hip arthroplasty. *Arch Orthop Trauma Surg* 1998;117:177-9.
48. Rask MR. Superior gluteal nerve entrapment syndrome. *Muscle Nerve* 1980;3:304-7.
49. Tesio L, Bassi L, Galardi G. Transient palsy of hip abductors after a fall on the buttocks. *Archives of Orthopaedic & Traumatic Surgery* 1990;109:164-5.
50. Maitland GD. Vertebral Manipulation. London: Butterworths, 1986.
51. Pace JB. Commonly overlooked pain syndromes responsive to simple therapy. *Postgrad.Med* 1975;58:107-13.
52. Saudek CE. The Hip. In Gould JA, Davies GJ, eds. *Orthopaedic and Sports Physical Therapy*, pp 365-407. St Louis: Mosby, 1985.
53. Beatty RA. The piriformis muscle syndrome: a simple diagnostic maneuver. *Neurosurgery* 1994;34:512-4.
54. Durrani Z. "Sciatic radicular pain" or piriformis muscle syndrome?. *Anesth Analg* 1989;69:260.
55. Wyant GM. Chronic pain syndromes and their treatment. III. The piriformis syndrome. *Can Anaesth Soc J* 1979;26:305-8.
56. Slipman CW, Vresilovic EJ, Palmer MA, Lipetz JS, Lenrow D. Piriformis muscle syndrome: A diagnostic dilemma. *J Musculoske Pain* 1999;7:73-83.
57. Nainzadeh N, Lane ME. Somatosensory evoked potentials following pudendal nerve stimulation as indicators of low sacral root involvement in a postlaminectomy patient. *Arch Phys Med Rehabil* 1987;68:170-2.
58. Synek VM. Short latency somatosensory evoked potentials in patients with painful dysaesthesias in peripheral nerve lesions. *Pain* 1987;29:49-58.
59. Karl RD, Jr., Yedinak MA, Hartshorne MF, Cawthon MA, Bauman JM, Howard WH *et al.* Scintigraphic

- appearance of the piriformis muscle syndrome. *Clin Nucl Med* 1985;10:361-3.
60. Almanza MY, Poon-Chue A, Terk MR. Dual oblique MR method for imaging the sciatic nerve. *Journal of Computer Assisted Tomography* 1999;23:138-40.
  61. Barton PM. Piriformis syndrome: a rational approach to management. *Pain* 1991;47:345-52.
  62. Chen WS, Wan YL. Sciatica caused by piriformis muscle syndrome: report of two cases. *J Formos Med Assoc* 1992;91:647-50.
  63. Jankiewicz JJ, Hennrikus WL, Houkom JA. The appearance of the piriformis muscle syndrome in computed tomography and magnetic resonance imaging. A case report and review of the literature. *Clin Orthop* 1991;205-9.
  64. Cohen BA, Lanzieri CF, Mendelson DS, Sacher M, Hermann G, Train JS *et al.* CT evaluation of the greater sciatic foramen in patients with sciatica. *AJNR Am J Neuroradiol.* 1986;7:337-42.
  65. Fröhlich D, Fröhlich R. Piriformis syndrome: Diagnosis and therapy. *Manuelle Medizin* 1995;33:1-6.
  66. Huber HM. [The piriformis syndrome—a possible cause of sciatica]. *Schweiz Rundsch.Med Prax* 1990;79:235-6.
  67. Julsrud ME. Piriformis syndrome. *J Am Podiatr Med Assoc* 1989;79:128-31.
  68. TePoorten BA. The piriformis muscle. *J Am Osteopath Assoc* 1969;69:150-60.
  69. Lewit K, Simons DG. Myofascial pain: relief by post-isometric relaxation. *Arch Phys Med Rehabil* 1984;65:452-6.
  70. Travell JG, Simons DG. Myofascial Pain & Dysfunction. The Trigger Point Manual. Volume 1. The Upper Extremities. Baltimore: Williams & Wilkins, 1983.
  71. Thiele GH. Coccygodynia and pain the superior gluteal region. *JAMA* 1937;109:1271-5.
  72. Hallin RP. Sciatic pain and the piriformis muscle. *Postgrad Med* 1983;74:69-72.
  73. Jan MH, Lin YF. [Clinical experience of applying shortwave diathermy over the piriformis in sciatic patients]. *Taiwan I Hsueh Hui Tsa Chih* 1983;82:1065-70.
  74. Graff-Radford SB, Reeves JL, Baker RL, Chiu D. Effects of transcutaneous electrical nerve stimulation on myofascial pain and trigger point sensitivity. *Pain* 1989;37:1-5.
  75. Hsueh TC, Cheng PT, Kuan TS, Hong CZ. The immediate effectiveness of electrical nerve stimulation and electrical muscle stimulation on myofascial trigger points. *Am J Phys Med Rehabil* 1997;76:471-6.
  76. Lee JC, Lin DT, Hong C-Z. The effectiveness of simultaneous thermotherapy with ultrasound and electrotherapy with combined AC and DC current on the immediate pain relief of myofascial trigger points. *J Musculoske Pain* 1997;5:81-90.
  77. Snyder-Mackler L, Bork C, Bourbon B, Trumbore D. Effect of helium-neon laser on musculoskeletal trigger points. *Phys Ther* 1986;66:1087-90.
  78. Snyder-Mackler L, Barry AJ, Perkins AI, Soucek MD. Effects of helium-neon laser irradiation on skin resistance and pain in patients with trigger points in the neck or back. *Phys Ther* 1989;69:336-41.
  79. Hanania M, Kitain E. Perisciatic injection of steroid for the treatment of sciatica due to piriformis syndrome. *Reg Anesth Pain Med* 1998;23:223-8.
  80. Pfeifer T, Fitz WF. [The piriformis syndrome]. *Z Orthop Ihre Grenzgeb.* 1989;127:691-4.
  81. Porta M. A comparative trial of botulinum toxin type A and methylprednisolone for the treatment of myofascial pain syndrome and pain from chronic muscle spasm. *Pain* 2000;85:101-5.
  82. Porta M, Loiero M, Gamba M, Luccarelli G, Fornari M. The use of botuline A toxin in the treatment of myofascial painful syndromes. *Riabilitazione* 1999;32:49-55.
  83. Porta M. Botulinum toxin type A injections for myofascial pain syndrome and tension-type headache. *European Journal of Neurology* 1999;6:S103-S109.
  84. Cummings TM, White AR. A systematic review of needling therapies in the treatment of myofascial pain. *Arch Phys Med Rehabil* (in press).
  85. Hanania M. New technique for piriformis muscle injection using a nerve stimulator. *Reg Anesth* 1997;22:200-2.
  86. Hughes SS, Goldstein MN, Hicks DG, Pellegrini VD, Jr. Extrapelvic compression of the sciatic nerve. An unusual cause of pain about the hip: report of five cases [see comments]. *J Bone Joint Surg Am* 1992;74:1553-9.
  87. Kouvalchouk J-F, Bonnet J-M, De Mondenard J-P. Piriformis syndrome. *Revue de Chirurgie Orthopedique et Reparatrice de l'Appareil Moteur* 1996;82:647-57.
  88. Lu MY, Dong BJ, Ma XY. [Piriformis syndrome and its operative treatment: an analysis of sixty cases]. *Chung Hua Wai Ko Tsa Chih* 1985;23:483-4, 510.
  89. Mizuguchi T. Division of the piriformis muscle for the treatment of sciatica. *Arch Surg* 1976;111:719-22.
  90. Nagi ON, Dhillon MS, Goni V. Does the piriformis compress the sciatic nerve during limb length equalization? *Singapore Med J* 1999;40:749-51.
  91. Park HW, Jahng JS, Lee WH. Piriformis syndrome—a case report. *Yonsei Med J* 1991;32:64-8.
  92. Solheim LF, Siewers P, Paus B. The piriformis muscle syndrome. Sciatic nerve entrapment treated with section of the piriformis muscle. *Acta Orthop Scand* 1981;52:73-5.
  93. Vandertop WP, Bosma NJ. The piriformis syndrome. A case report. *J Bone Joint Surg Am* 1991;73:1095-7.
  94. Neundorfer B, Jaspert A, Grehl H. Nerve entrapment syndromes: Non-surgical treatment and postoperative care. *European Journal of Physical Medicine & Rehabilitation* 1993;3:60-8.
  95. Stein JM, Warfield CA. Two entrapment neuropathies. *Hosp Pract (Off Ed)* 1983;18:100A, 100E, 100H.

## Quote:

*“Care more for the individual patient than for the special features of the disease.”*

**Sir William Osler**