

Low back pain assessment for the medical acupuncturist

Mike Cummings

Summary

Low back pain frequently presents to medical acupuncturists, many of whom are general practitioners working in the public sector. Under these circumstances there is often limited time to devote to an initial assessment of a patient's presenting complaint. This paper presents an assessment process that is aimed at informing management decisions for medical acupuncturists, although much of the process may be useful to a wider range of practitioners. The assessment is divided into an initial screening procedure, and a further more detailed assessment. The initial screening procedure can usefully be applied in a brief consultation. Using this assessment tool, practitioners with medical acupuncture training will be able to select the cases most likely to be helped by their acupuncture skills.

Keywords

Low back pain, assessment, medical acupuncturist.

Introduction

Low back pain (LBP) frequently presents to medical acupuncturists,¹ many of whom are general practitioners (GPs) working in the public sector. Under these circumstances there is often limited time to devote to an initial assessment of a patient's presenting complaint. In the UK, GPs often report that they have inadequate training to assess musculoskeletal conditions. Low back pain is one of the most commonly presenting musculoskeletal conditions and it is one of the most challenging to assess.² The combination of these factors often leads GPs to avoid any form of physical assessment of patients presenting with low back pain.

The aim of this article is to describe the assessment process developed by the author, which begins with a screening tool that can be applied in a short consultation. The process can take as little as five minutes, and can usefully guide further management. Following this screening, the practitioner may need to conduct a longer assessment with a view to treatment with acupuncture. Rarely, the patient will need referral for specialist assessment and treatment.

The assessment process described was developed over 15 years, and it was influenced primarily by clinical observation and training with

many different practitioners, to whom the author is grateful. Impressions gained from clinical practice can be very unreliable, although in this field there is often little else to guide the practitioner. The author presents some results from retrospective audit of his initial years of using acupuncture which, whilst very limited, support some elements of the decision-making process.

Readers who have received specific training in the assessment of low back pain may also find some of the processes useful, though they will clearly have their own system and schedule of assessment. This article is aimed primarily at practitioners with limited time for initial assessment, and the author hopes that after studying the procedure, practitioners will look forward to their next low back pain patient with eager anticipation rather than with dread.

Initial assessment

This section includes the most useful features of a brief history and examination of a patient with LBP being assessed for the first time. The focus is on a time-efficient pragmatic process, and it is presented in a roughly chronological order, rather than in the standard division of history and examination, since these can be performed simultaneously to some extent.

Mike Cummings
medical director
BMAS

london@thebmas.com

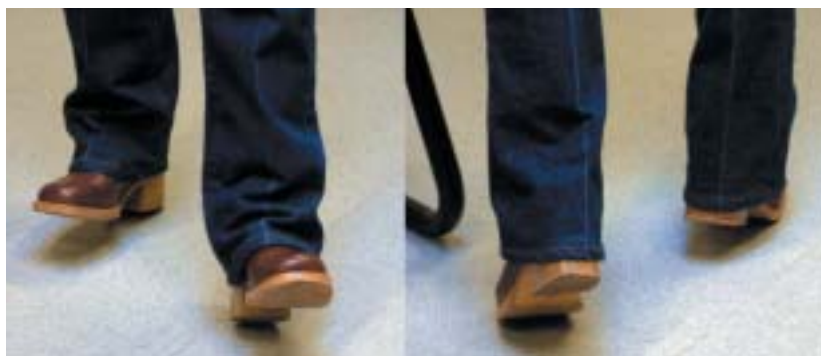

Figure 1 Heel walking (left image): this requires strong contraction of tibialis anterior (L4/5), and to a lesser extent, extensor digitorum longus and extensor hallucis longus (L5/S1). Toe walking (right image): this requires strong contraction of gastrocnemius and soleus (S1/2).

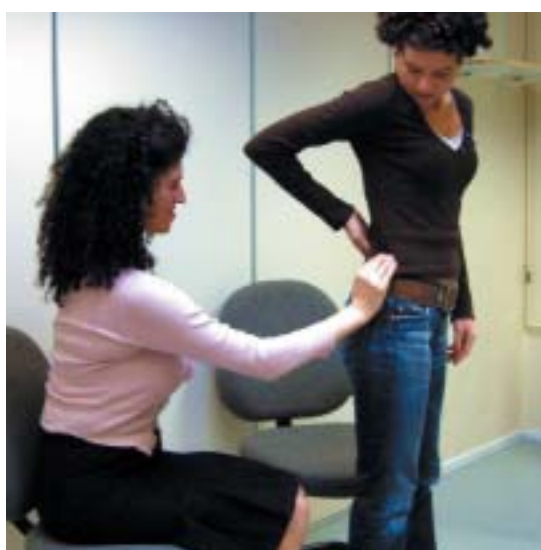

Figure 2 Point to the pain: ask the patient to point to the site of pain, and indicate its extent and any radiation. It is important to palpate the upper iliac crest for orientation.

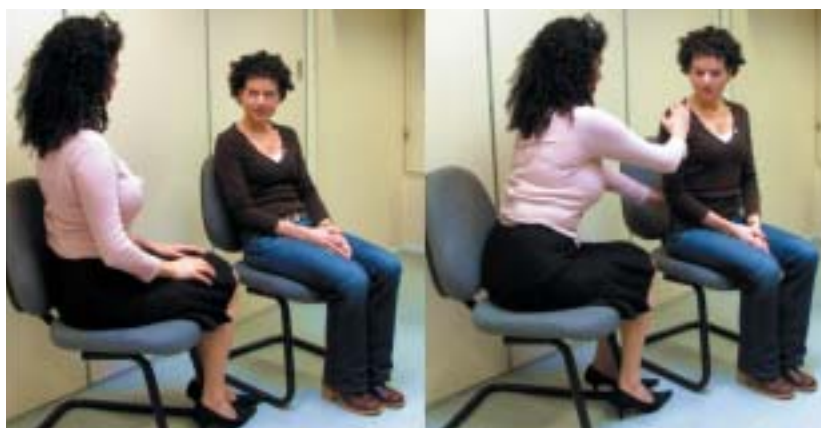

Figure 3 Ensure that the patient is sitting upright maintaining a lumbar lordosis before performing the seated straight leg raise (seated SLR).

Initial screening procedure

The patient arrives (usually walking into a consultation room) with the presenting complaint of low back pain. Before inviting them to sit, screen for gross motor neuropathy by observing them walking on their heels (see Figure 1) and then on their toes (see Figure 1). Ensure that you can see air under the forefoot during heel walking, and under the heels during toe walking. Baggy trousers can be held up by the patient, and footwear does not necessarily need to be removed at this stage provided that it permits active dorsiflexion and plantar flexion at the ankle. Heel walking tests for a footdrop, ie motor weakness of L4 and L5 (note that a specific test for L5 [extensor hallucis longus - EHL] is performed later). Toe walking tests for motor weakness in S1/2.

Just before the patient sits down, ask them to point to the site of pain and indicate its extent and radiation. As the patient will be clothed, it is important to palpate the upper iliac crest for orientation (see Figure 2). Take this opportunity to ask the patient to describe the nature or character of the pain. Try not to lead the patient by asking a closed question with the description that you expect, eg 'Is it a dull aching pain?' However, if the patient is struggling to answer, give a series of options, eg 'Is your pain burning, aching, throbbing...?' With reference to any radiation, find out whether the pain spreads slowly in a vague and diffuse manner, or whether it shoots quickly in a narrow band (discussed below).

Once the patient is seated, ensure that they are sitting upright by placing the palm of one hand behind the patient's back at the level of the lumbar lordosis (see Figure 3). Keeping this hand in place to maintain the lordosis, ask the patient to straighten one leg (see Figure 4). If the patient has already described pain down one leg, always start with the non-painful leg. If the patient manages to fully straighten the leg in the upright seated position, this approximately equates to 90° straight leg raising (SLR) in the more traditional position (lying supine on an examination couch).

The bowstring test of the tibial nerve is arguably the best test for sciatic tension. It involves flexion of the hip to around 90°, slight flexion of the knee and full dorsiflexion of the foot so that the tibial nerve can be palpated as

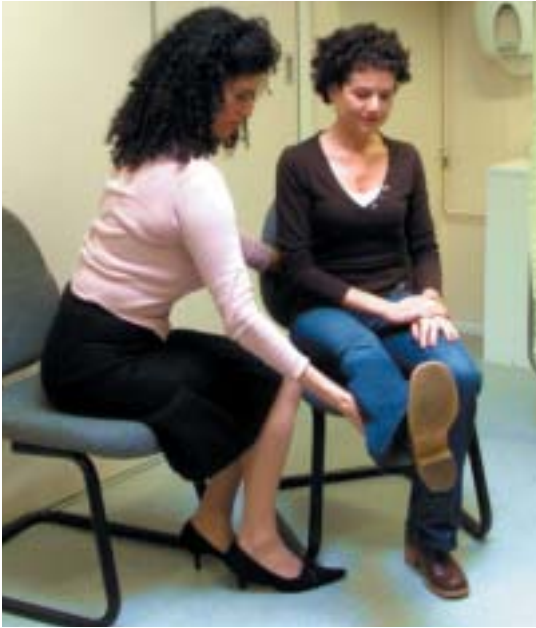

Figure 4 Seated SLR: with a hand maintaining the lumbar lordosis, the examiner asks the patient to straighten each leg individually, starting with the non-painful side. If the knee is straightened in this position the manoeuvre equates to a supine SLR of 90°.



Figure 5 Seated bowstring: note that the examiner controls the degree of hip and knee flexion in order to achieve tension on the tibial nerve, but maintains a comfortable position for the patient. In the figure the examiner's right hand is holding the patient's foot in full dorsiflexion, and the pad of her left thumb performs the bowstring manoeuvre.

a longitudinal cord in the popliteal fossa. Pressure on this cord applies isolated tension to the sciatic nerve and its roots. The advantage of this test is that the final 'bowstring' manoeuvre is performed with the rest of the body stationary, so that the response produced can be solely attributed to tension in the sciatic nerve, provided, of course, that there is no local pathology in the popliteal fossa. The test can be performed in the seated patient (see Figure 5). It is important that the patient is comfortable, and if possible without pain. A position must be found by the examiner in which they can feel the tibial nerve under tension, before pressure is applied to the nerve with the pad of either the thumb or two fingers (usually the middle and ring fingers). The movement applies gentle pressure to the nerve, rather than plucking it like a guitar string. The latter can be very uncomfortable. This manoeuvre normally produces a sensation of neural tension at the back of the knee and to a variable degree down the leg. The test is positive if it reproduces the patient's complaint of back or leg pain or both. The patient does not need to sit upright for this procedure; however, if the individual is very supple, it may be necessary to ask them to slump forward to tension the neural structures from above (see Figure 6).

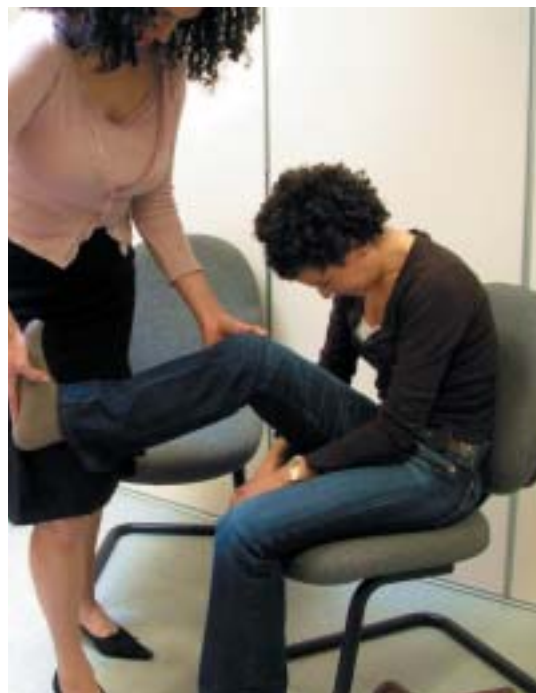

Figure 6 Seated bowstring with slump: this manoeuvre is used for supple patients in order to detect very subtle degrees of neural irritation.



Figure 7 Knee jerk: in this figure the examiner's left hand is placed on the top of the knee, and the thumb of the same hand feels for the patella tendon. This position allows the examiner to both target the tendon accurately, and to relax the patient's leg by gently shaking the knee from side to side.

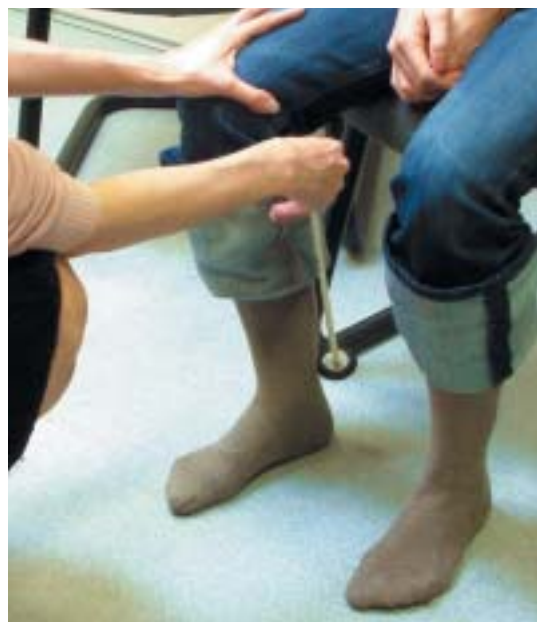

Figure 8 Ankle jerk: note that the patient's feet are placed so that the heels are behind the vertical plane of the knee. This results in slight dorsiflexion of the ankle, stretching soleus and the Achilles tendon slightly. Gastrocnemius is not stretched since it attaches above the knee, which is flexed. In the figure, the examiner's right hand is resting on the patient's knee to help to relax the leg by gently shaking the knee from side to side. A normal ankle reflex will result in the heel lifting involuntarily. This reflex can be reinforced in the standard manner, by asking the patient to grip their hands together and try to pull them apart, just as the Achilles tendon is struck with the tendon hammer.

Lower limb reflexes can be tested in the seated position as shown in Figures 7 and 8. It is not possible to detect subtle differences between sides in this manner; however, the examiner is only really interested in the presence or absence of reflexes when performing a screening assessment for LBP. Plantar reflexes can also be tested in this position.

Testing the power of extensor hallucis longus (EHL) is a particularly important manoeuvre, since weakness of this muscle may be the only sign of motor neuropathy in an acute L5 nerve root compression. The patient is asked to 'lift both big toes and keep them up', and the examiner presses firmly with the same digit of each hand onto the interphalangeal joint of each great toe (see Figure 9). Normally it is not possible to press the toe back to the floor.

The examiner may include a test for gross sensory loss in the dermatomes of the lower leg (see Figure 10). One finger pad of each hand is run simultaneously over the same areas of both legs, and the patient is asked whether it feels the same on both sides. The outer aspect of the lower leg corresponds to the L5 dermatome, and the inner aspect corresponds to L4. The outer aspect of the foot is S1. This distribution of dermatomes occurs in over 75% of the population.³

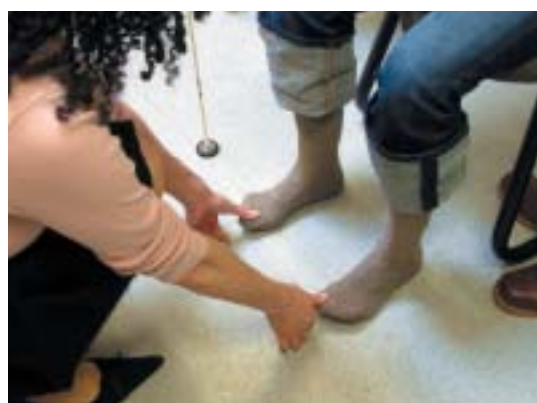

Figure 9 EHL power: the patient is asked to 'lift both big toes and keep them up', while the examiner presses firmly with the same digit of each hand onto the interphalangeal joint of each great toe. Normally it is not possible to press the toe back to the floor.

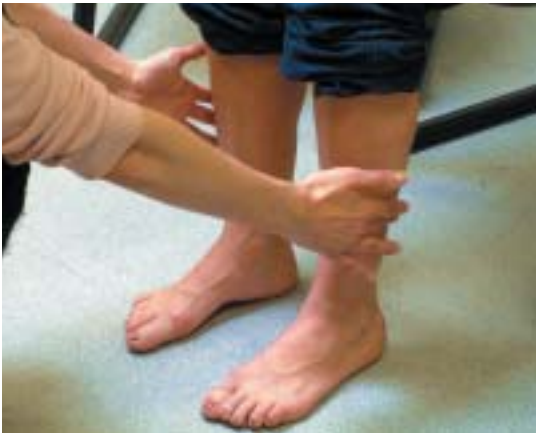

Figure 10 Testing sensation: one finger pad of each hand is run simultaneously over the same areas of both legs, and the patient is asked whether it feels the same on both sides. The outer aspect of the lower leg is the L5 dermatome, and the inner aspect is L4. The outer aspect of the foot is L5.

At this point the examiner may have decided to extend the assessment, and probably requires the patient to stand up. This is an opportunity to test quadriceps power (L3/4) by asking the patient to stand up from the chair using one leg only

(keeping the other leg off the floor), each leg in turn. If the circumstances do not allow for this test, eg the chair height is too low for the patient to realistically achieve the task, an alternative may be to ask the patient to stand up using both legs with the feet placed in a wide stance (two shoulder-widths apart). Any unilateral quadriceps weakness should be obvious from the patient having to support their weight on that side.

Initial categorisation and management decision

Following the initial screening (summarised in Box 1), it should be possible to place the patient's LBP presentation into one of three categories (see flow diagram). Red flag symptoms and signs (those that may indicate serious underlying disease; see Box 2), and signs that indicate nerve root compression (if they have not already been assessed by a specialist) generally should indicate referral to an appropriate specialist. Since testing for motor neuropathy in the screening procedure above is more objective than the assessment of skin sensation, clear motor weakness is the key finding that suggests nerve root compression. The test of skin sensation is used only for confirmation.

Box 1 Initial screening checklist

Heel / toe walking	testing for motor weakness – L4/5 (heel walking); S1/2 (toe walking)
Point to pain	place a hand onto the upper surface of the nearest iliac crest for orientation – this is approximately the L4 level
Nature of pain	ask the patient what the pain feels like
Seated SLR	ensure that the lumbar lordosis is maintained by placing one hand between the patient's lumbar spine and the back of the chair
Seated bowstring	position the patient so that they are comfortable (ie not in pain) and so that you can feel a central cord in the popliteal fossa of the side being tested; the only movement must be to put pressure on the cord (tibial nerve)
Reflexes	knee and ankle jerks and the plantar reflexes can be tested in the seated position
EHL	test the power of extensor hallucis longus (L5) by pressing over the interphalangeal joint of both big toes at the same time with the same digit of each hand

These last two items can be missed out of the initial screening:

Sensory loss	lightly run one finger pad of each hand simultaneously over the same areas of both legs – L4 to S1 dermatomes can quickly be screened for gross sensory loss in this way
Quadriceps power	ask the patient to stand up from the chair using one leg, ask them to repeat the manoeuvre with the other leg – this requires strong contraction of the quadriceps (L3/4)

Box 2 Red flags

Bilateral sciatica, saddle anaesthesia and disturbance of bladder/bowel function suggest cauda equina compression from a central disc prolapse – requires acute surgical assessment

Pain that is worse at rest, and unrelated to mechanical events – consider neoplasia

Weight loss and/or fever – consider neoplasia, infection

Past history of HIV, TB, neoplasia or steroid use

Commonest tumours to metastasise to bone are: breast, bronchus, kidney, thyroid and prostate

Consider rare conditions such as spinal infection or dissecting aortic aneurysm

Box 3 Symptoms and signs of ‘neural irritation’

Symptoms

Sharp shooting (lancinating) pain down the leg

Band-like pain $\leq 5\text{cm}$ width³

Signs

Positive bowstring

Seated SLR reproduces pain before leg is straightened

SLR (supine) reproduces pain at $\leq 45\%$

Positive femoral stretch test

Clinically apparent nerve root compression is a rare finding, but it is important to detect so that the patient can receive early definitive treatment.

The remaining (vast majority) of patients are divided into two categories based on the presence of symptoms and signs of ‘neural irritation’ (see Box 3), principally positive sciatic tension signs (bowstring test). There are theoretical and practical differences between these two categories: theoretical, in terms of the likely source of LBP; and practical, in terms of the prognosis with acupuncture treatment. If neural tension reproduces the patient’s pain complaint, the source of pain is likely to be somewhere along the track of the nerve, its roots, or its dural connections. The remaining category, which has been given the label ‘mechanical back pain’, is likely to contain a greater proportion of patients with myofascial pain, and therefore the practitioner can probably expect a better prognosis following acupuncture or dry needling.

Further assessment

This section is not in a strict chronological order, since the further assessment of LBP will depend on the findings from the screening assessment – in particular the presence of symptoms or signs of neural irritation, and the site and radiation of the pain. Also, this section is not comprehensive, in that it cannot include all the possible assessment procedures for LBP. It includes a selection of the more useful techniques, and is targeted towards helping to determine the likely source of pain and the presence of myofascial trigger points, since these are important in informing the western medical acupuncture approach to treatment.

Pain history

Given more time for an assessment it is useful to take a detailed history of the pain and its associated features. In a dedicated clinic, where the patients are attending for acupuncture treatment or for assessment of back pain, it may be useful to give them a pain history sheet to fill in before they are seen. In the BMAS London Teaching Clinic, the author uses a pain history sheet with a body diagram (which is available to download from the clinic page of the BMAS website).⁴ The patient is asked to fill in details such as those listed in Box 4, and draw the site of pain on the body diagram. The author finds this process useful, but it is important to note that the patient may not accurately draw the location of their pain, and it is important to confirm the site of pain by asking the patient to point directly to it and indicate any radiation.

Box 4 Pain history

Key elements

Site [including radiation]

Nature [plus severity]

Chronology

Onset

Duration

Frequency

Special times of occurrence

Relations

Exacerbating factors

Relieving factors

Associated symptoms

Standing

There are a series of assessment procedures that can be performed usefully and quickly following the initial screening, just as the patient stands up. It is helpful to have good exposure of the spine and legs, and this is certainly appropriate for a full assessment, although these tests can be performed with more limited exposure during a short assessment.

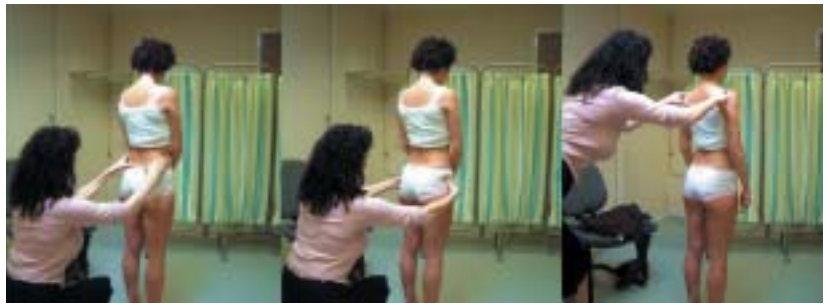

Figure 11 Assessment of asymmetry: with the patient standing erect the examiner estimates the relative height of the upper iliac crests and posterior superior iliac spines (left image), the top of the greater trochanters (middle image), and the acromioclavicular joints (right image).

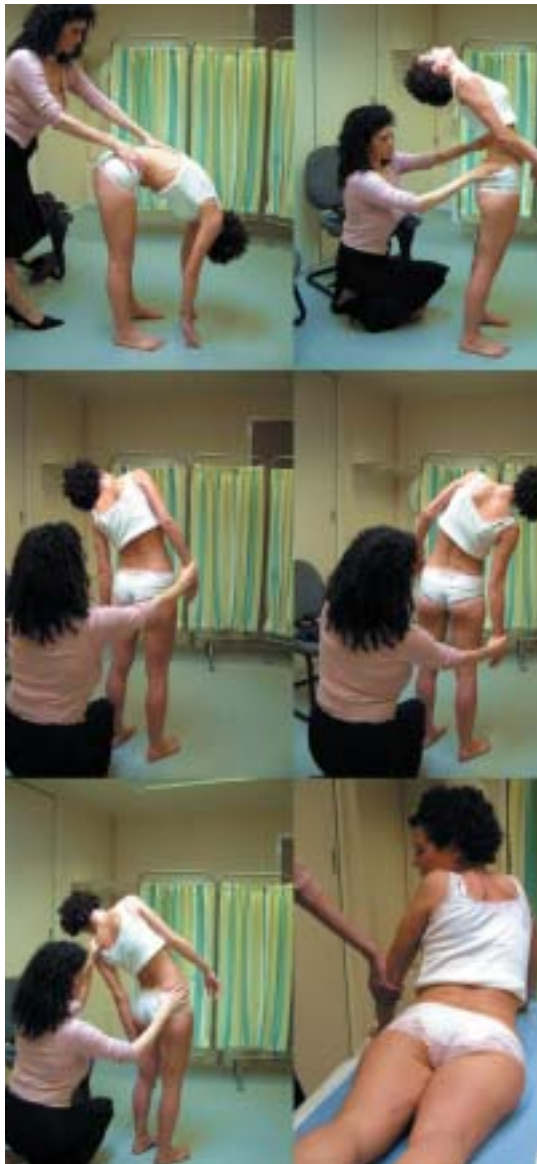

Figure 12 Lumbar spine movements (standing): these include flexion and extension (upper images); note the placement of the examiner's hands), lateral flexion (middle images), and a combination movement of lateral flexion with extension and ipsilateral rotation in two different positions (lower images) to load or compress the ipsilateral lumbar zygapophyseal joints.

Observing the patient from the back the practitioner can note any postural asymmetries (see Figure 11). The relative heights of the upper iliac crests are noted, and any difference can be compared with the same assessment of the heights of the greater trochanters. These measures will give an indication of any gross leg length inequality and possibly pelvic torsion. The relative heights of the upper iliac crests can also be compared with the relative heights of the acromioclavicular joints. If both iliac crests and acromioclavicular joints (ACJ) are level, the spine is likely to be straight (in the coronal plane). If both slope the same way (eg both the left iliac crest and left ACJ are lowered), the spine is likely to form an S-shape. If the slopes are opposite (eg the left iliac crest is low but the left ACJ is high), the spine is likely to form a C-shape. The shape can be confirmed by direct observation and palpation of the whole spine. The relevance of such asymmetries may help the practitioner in assessing the loading of spinal elements, and in identifying the likely areas to examine the paraspinal muscles for shortening. Lumbar zygapophyseal joints (ZAJ) are likely to undergo more mechanical loading on the concave side of a lateral spinal curve, and the long paraspinal muscles are allowed a greater degree of shortening on the concave side, and therefore may be more prone to developing TrPs.

Lumbar movements (with the exception of rotation) can be quickly assessed in the same position (see Figure 12). It is useful to place a digit of one hand on the spinous process (SP) of L1 and a digit of the other hand on the spinous process of

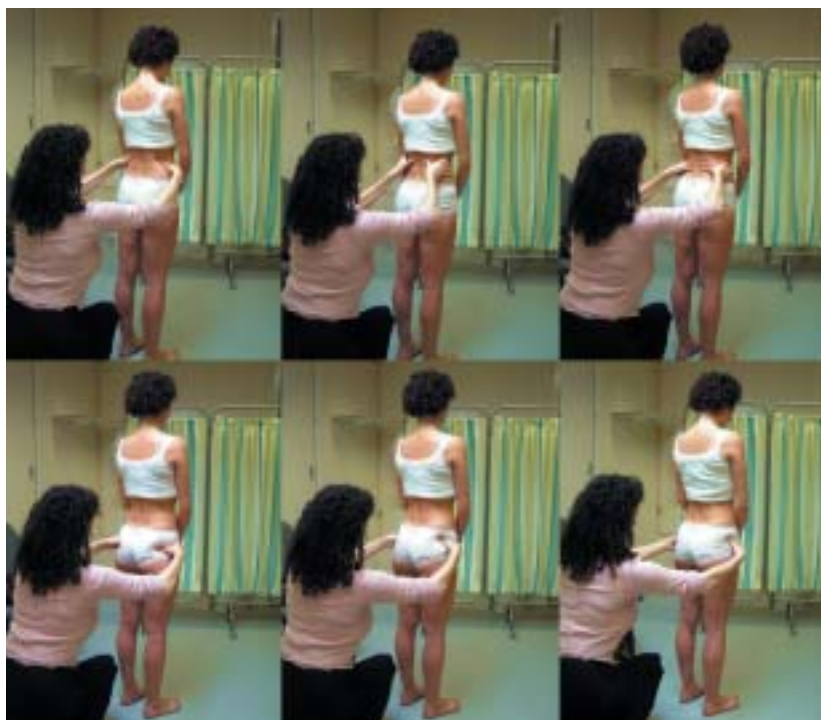

Figure 13 Screening for tender and trigger points (standing): the images illustrate palpation of quadratus lumborum (upper left image), erector spinae (upper middle and right images), piriformis (lower left image), posterior fibres of gluteus medius (lower middle image), and middle fibres of gluteus medius and minimis (lower right image).

S1 during flexion and extension, to assess the range of lumbar movement more easily. The practitioner does not have to be absolutely accurate in finding the spinous processes of L1 and S1, but it is worth briefly palpating the posterior superior iliac spine (PSIS) to find S1 (upper border of PSIS), and palpating the 12th rib just lateral to the bulk of erector spinae to estimate the level of L1. Flexion increases the pressure in the intervertebral discs, and stretches the paraspinal muscles: extension loads the posterior columns and ZAJs, and relaxes the paraspinal muscles. Lateral flexion (see middle images of Figure 12) loads the discs and ipsilateral posterior column and ZAJs, and stretches the contralateral musculature. If pain is provoked by any of these movements, the examiner confirms the location (central, ipsilateral, contralateral) and nature of the pain, including whether the pain is recognised as the patient's pain complaint. Firm conclusions cannot be drawn from these provocation tests; however, the information may help support or refute tentative ideas about the origin of the patient's pain.

As well as flexion, extension and lateral flexion, it can be useful to ask the patient to perform a combination of extension and lateral flexion (with a degree of ipsilateral rotation). The author usually asks the patient to 'twist around and reach down the back of one leg'. The position is assisted by the examiner placing one hand on the contralateral hip and the other on the ipsilateral shoulder. This manoeuvre puts extra pressure onto the ipsilateral posterior spinal columns and ZAJs. If it reproduces the patient's ipsilateral LBP, it supports the notion that the pain may be derived from a lumbar ZAJ (note that this is not a specific provocation test for ZAJ pain). Some patients find it too painful to adequately perform this manoeuvre from a standing position. If so, the same spinal position can be achieved with much less loading lying on a couch (see bottom right image in Figure 12). It should also be noted that this manoeuvre narrows the spinal foramina on the ipsilateral side, so ipsilateral lancinating pain of intense paraesthesiae in the leg may indicate nerve root impingement, although this is an uncommon finding in a primary care population.

Before moving to the examination couch, it can be useful to perform a quick screening for muscular tenderness and trigger points (TrPs) in the lumbogluteal area (see Figure 13). The main advantage of doing this whilst the patient is standing is so that both sides can be palpated at once to compare relative tenderness. This is particularly useful in cases where the pain distribution is lateralised, and it saves time in getting the patient to roll over on an examination couch to make a comparison with the non-painful side.

Sitting

There are a number of tests that can be performed with the patient sitting on an examination couch. Indeed much of the initial screening procedure above can be performed in this position. The only main exceptions are in the testing of the ankle jerk and EHL power, since the patient's feet are unlikely to reach the floor.

If a marked leg length inequality has been noted previously, it is useful to assess the relative heights of the upper iliac crests again with the patient sitting. This will give an indication of the relative size of each hemipelvis (see upper image in Figure 14).

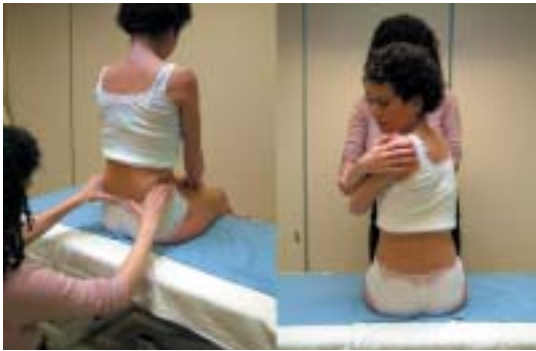

Figure 14 Sitting on an examination couch: this position can be used to assess the relative size of each hemipelvis (left image), which is relevant to an assessment of asymmetry. The right image illustrates an assessment of spinal rotation, which is much easier to perform with the patient seated on a couch.

If the practitioner wishes to assess spinal rotation, this is best performed in the sitting position (see lower image in Figure 14). The patient is asked to put their knees together and cross their arms over the front of their chest with a hand on each shoulder. The patient's knees are gripped by the thighs of the examiner and the patient's contralateral shoulder and elbow can be used to guide passive or active rotation.

Lying

When the practitioner asks the patient to lie on the examination couch, there are four possible positions to choose – prone, supine, left lateral or right lateral. The supine position can be used to perform the standard SLR and bowstring, and is the more classical position for testing reflexes and sensation in the lower extremity. It is also useful for assessing the hip and knee joints if there is some diagnostic confusion about their contribution to leg pain in a patient with back and leg pain. Finally this position can be used to perform stress tests on the joints of the pelvis.

The prone position is suitable for palpating the spinous processes and deep paraspinal muscles (see Figure 15). The muscles of the hand and wrist are not strong enough to assess posterior anterior movement of the lumbar spinous processes, so the weight of the upper body is used through straight arms and fixed thumbs (see left diagram of Figure 15). Pressure is applied to each spinous process in

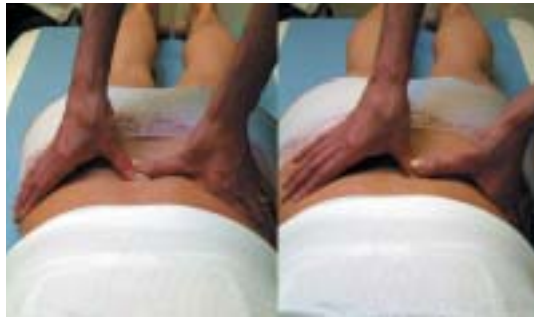

Figure 15 Lying prone: the left image illustrates how pressure can be applied to the lumbar spinous processes to assess posterior anterior movement and pain provocation. The right image illustrates palpation of deep paraspinal muscles. Constant firm pressure is applied, and the thumbs are moved in a cranial and lateral direction so as to cross the fibres of multifidus.

turn, the relative stiffness can be gauged, and the patient can be asked about reproduction of their symptoms. A similar technique can be used to apply pressure to the paraspinal musculature. This time, however, the pressure is maintained, and the thumbs are moved in a cranial and lateral direction across the fibres of multifidus. The fibres of this deep muscle layer cannot be felt, but tenderness from deep TrPs is more likely to be generated by applying pressure in a direction across the fibres. The assessment of this layer may proceed to dry needling, using the needle as an extension of the examiner's fingers to apply a pressure stimulus to different muscle layers and elicit feedback from the patient regarding pain reproduction.

Cases of LBP that are more likely to respond to brief needling interventions at the initial assessment are those with unilateral pain and no neural irritation. The exception to this is piriformis syndrome, which may present with signs of neural irritation. Piriformis syndrome is the subject of a previous paper by the author.⁵ Patients with unilateral pain are best assessed in side-lying with the painful side uppermost (see Figures 16 and 17). In this position with the upper knee tucked behind the lower knee, the quadratus lumborum can be examined and treated (see upper image of Figure 16). This leg position is also used for palpation of the hip abductors – gluteus medius and minimis (see lower image in Figure 16). Piriformis is assessed with the upper

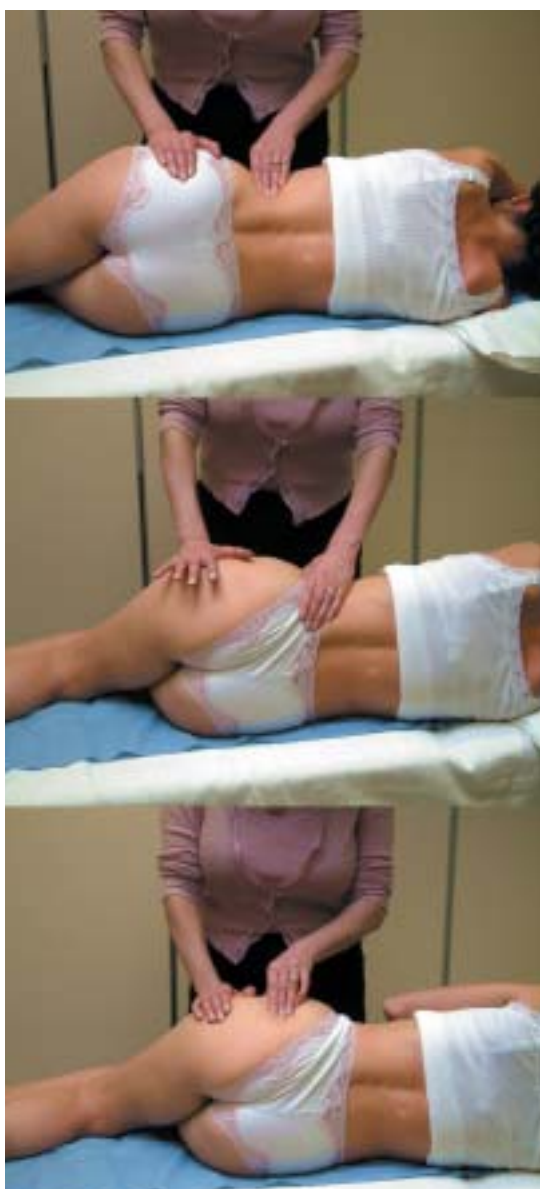

Figure 16 Side-lying 1: the upper image illustrates the position for examination of quadratus lumborum. Note that the upper knee is tucked in behind the lower knee, which fits the pelvis and increases the gap between the iliac crest and the 12th rib. In the middle image, the examiner is palpating the upper iliac crest and the greater trochanter prior to palpating across the fibres of the hip abductors (lower image).

flexed 90 degrees at the hip and fully adducted. This position puts the muscle on stretch and makes it easier to examine through the bulk of gluteus maximus (see Figure 17). It is also easier to needle in this position since an increase in resistance of needle insertion can generally be detected on reaching this muscle layer.

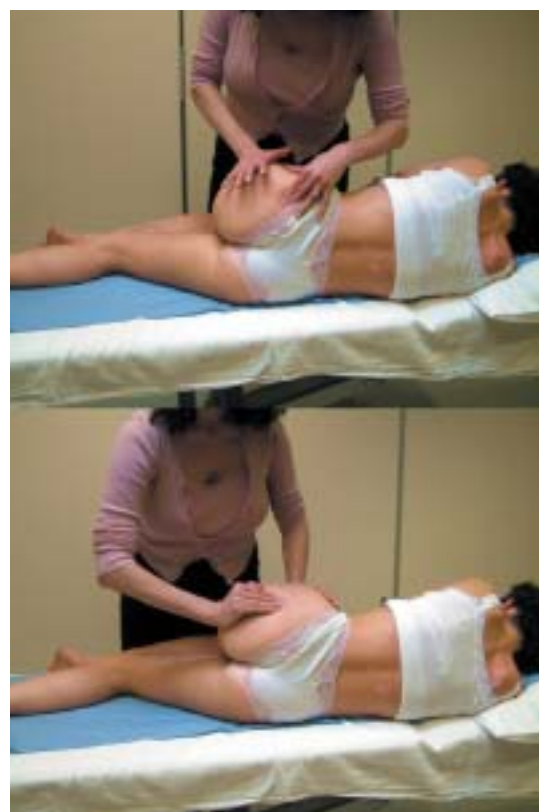

Figure 17 Side-lying 2: this is the best position for examining piriformis, with the upper leg flexed at 90° at the hip and the thigh fully adducted. In the upper image the examiner is palpating the greater trochanter and the sciatic notch. Pressure can be applied to the more medial portion of piriformis in the sciatic notch. The lower image illustrates palpation across the fibres of piriformis more laterally. Piriformis is palpated through gluteus maximus, and is felt as a step up when palpating in a cranial direction.

Other techniques

Sometimes it is very difficult to assess a patient's spinal movement in a standing position because of pain. Under these circumstances it is best to unload the spine by asking the patient to take up a position on their hands and knees on the examination couch. The hands are placed roughly shoulder width apart, as are the knees. In this position, lumbar spine flexion and extension can be performed with considerably less pain (see upper images of Figure 18). The complete range of flexion and extension cannot be reproduced in this stance, but can be achieved relatively easily with modifications (see lower images in Figure 18). Another advantage of this examination is that by the end of the process

the patient has learnt a simple and safe back exercise that they can use at home.

Finally, whilst there are many other procedures and tests for the assessment of LBP, space permits including only the nerve tension tests for the lower extremity (see Figure 19). Modifications to the bowstring test have been described in detail above, but it is important to note that the test was originally described with the patient lying on the examination couch (see upper image of Figure 19).⁶ The other nerve tension test for the lower limb is known as the femoral stretch test (see lower image of Figure 19). It is very unusual for this test to be positive, as the femoral nerve derives from the spinal nerves of L2 to L4, and these are rarely affected in patients presenting with LBP for the first time.

The value of assessment in predicting the response to acupuncture

A retrospective clinical outcomes audit was performed on data collected from 96 patients with

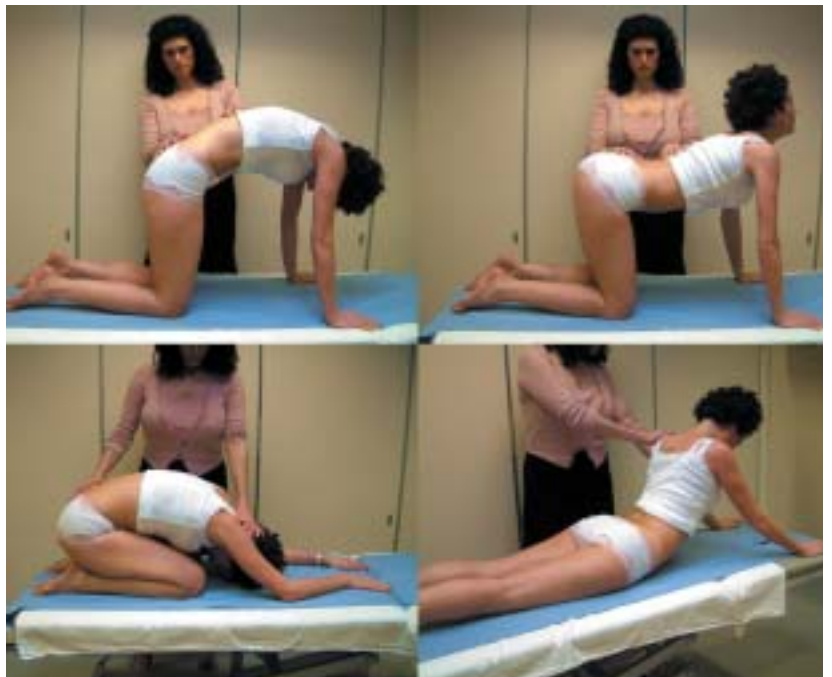

Figure 18 Lumbar spine movements (cat position): this manoeuvre is particularly useful to assess flexion and extension of the lumbar spine in a patient who is restricted by excessive pain in performing the movements when standing (upper images). The lower images illustrate modifications to the manoeuvre in order to assess the full range of lumbar flexion and extension..

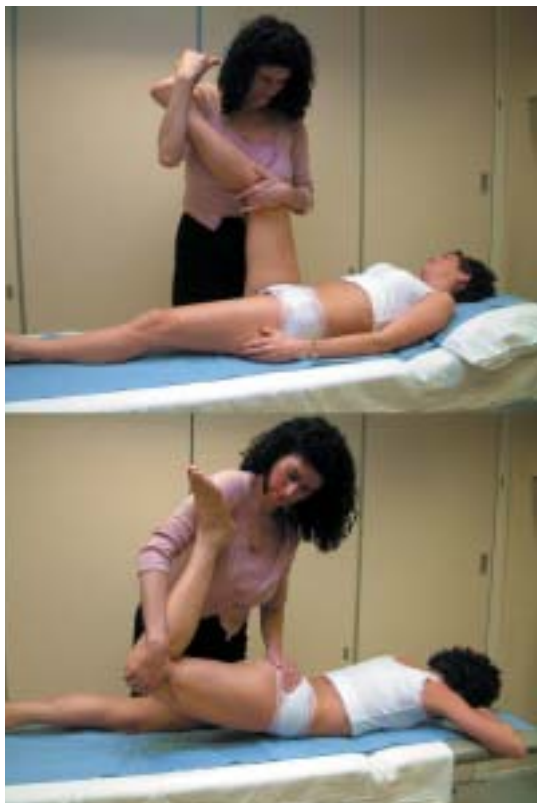

Figure 19 Nerve tension tests for the lower extremity: the upper image illustrates the position used for performing the bowstring test with the patient lying. The lower image illustrates the femoral stretch test.

LBP out of 520 seen by the author between 1993 and 1998. Data included: diagnostic category, the presence of tender points (TePs) and outcome. Outcomes were determined by the author based on either absolute change ('excellent' = cure or complete relief of symptoms; 'nil' = no change) or patient behaviour ('good' = symptom relief or control and patient does not seek other treatment; 'fair' = some symptom relief, but patient seeks other treatment for the complaint). 'Excellent' or 'good' outcomes were considered successful.

The results (including subgroup analysis) are displayed in Table 1. The results indicate a greater overall success rate for acupuncture treatment in LBP compared with LBP and sciatica or sciatica alone. Of 68 patients in whom the presence or absence of TePs was noted, the success rate in the presence of TePs was 67% and in the absence of TePs it was only 27%.

Discussion

This paper describes an assessment process for presentations of LBP, which can be tailored to the

Table 1 All low back pain cases, 1993 to 1998 (total audit population n=520)

Sub-category	Total	nfu	TePs present number (%)	Successful outcomes number (%)
All	96	18	47 (49)	55 (57)
LBP	54	6	27 (50)	37 (69)
LBPS	30	9	15 (50)	13 (43)
S	12	3	4 (33)	5 (42)

LBP: low back pain; LBPS: low back pain with sciatica; S: sciatica alone; nfu: no follow-up after initial assessment (considered as failures of treatment when calculating percentages); TePs: tender points (this group includes trigger points [TrPs], but not all TePs can be considered to be TrPs); Successful outcomes: 'excellent' or 'good' responses as rated by the author (see text for a full description).

consultation time available to the practitioner. It begins by screening for the presence of nerve compression, which usually will require referral for specialist assessment, and practitioners are reminded to be alert to the presence of 'Red flag' symptoms and signs (those that may indicate serious underlying disease; see Box 2). Further screening aims to differentiate the remaining patients (the vast majority) into those with neural irritation (see Box 3), and those without (labelled 'mechanical back pain' in the flow diagram). The latter group can be assessed further for the presence of tender points (TePs) or trigger points (TrPs), since these are a potential target for acupuncture treatment, and since simple audit suggests that this subgroup has the best response rate to acupuncture treatment.

In the opinion of the author, the most reliable indication of neural irritation in patients presenting with LBP is the bowstring test or some modification of this test; however, other features of the history and examination help to confirm the diagnosis (see Box 3). The author's audit data do not specifically note the presence of 'neural irritation', although this was one of the key features used to classify cases within the diagnostic categories of LBPS and S as opposed to LBP. The audit data suggest therefore that a successful outcome is less likely in the presence of neural irritation. It should be noted that piriformis syndrome with sciatic irritation is probably an exception to this.

Practitioners who chose to train in Western medical acupuncture are often uncertain of the difference between TePs and TrPs. TrPs are a subset of TePs, but not all TePs are TrPs. A TeP is

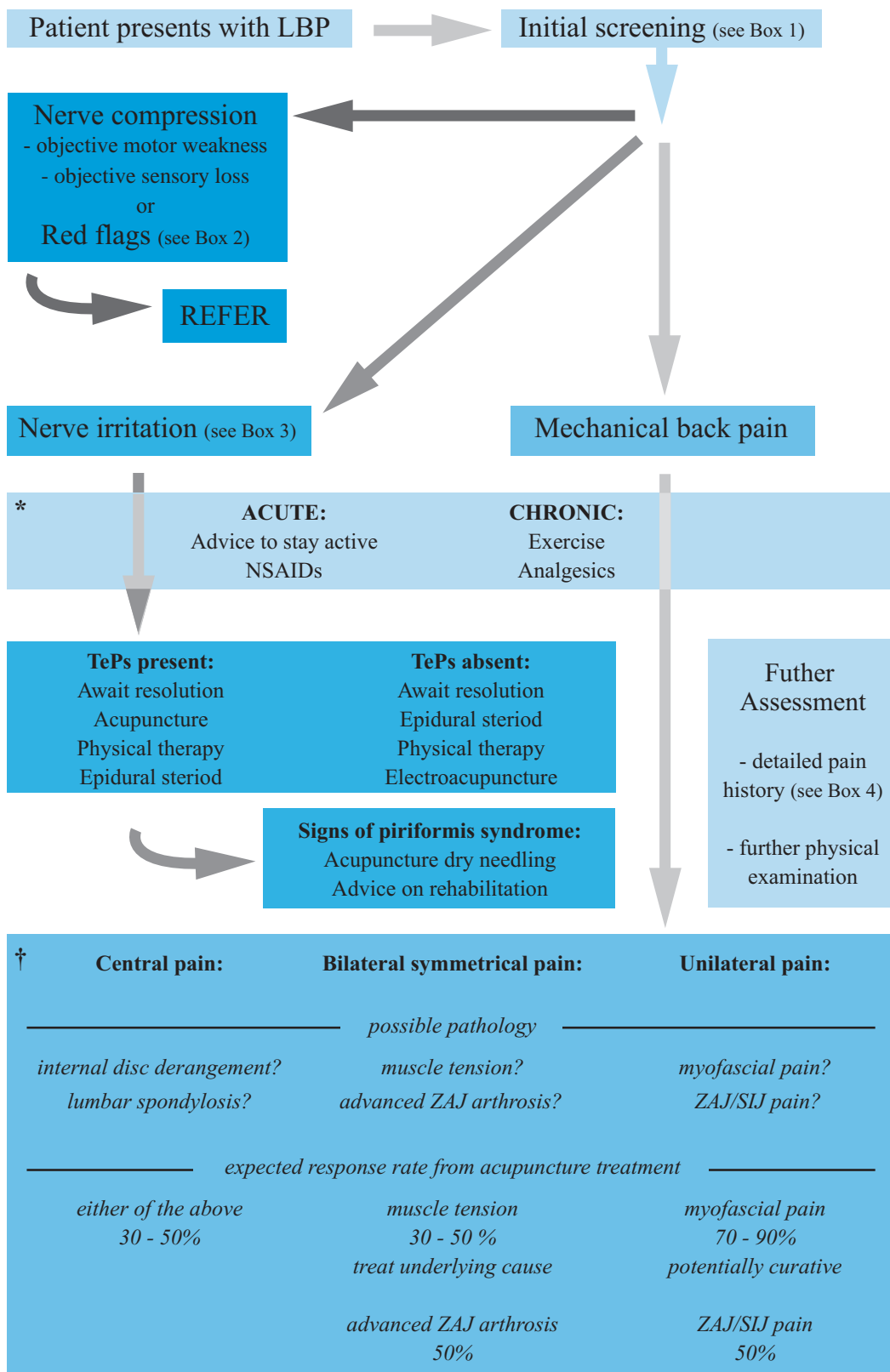
simply a spot that produces more pain on compression than the surrounding tissue. To be certain that a TeP found on examination is an active TrP, it must be a discrete spot in a taut band of skeletal muscle, and when compressed or needled it should reproduce pain that is recognised by the patient as part of their complaint. In the first few years of the author's practice, a clear distinction was not always made between TePs and TrPs, so the audit data refer to TePs only. The majority of these are likely to be TrPs, both primary and secondary, in the muscles of the back and hip girdle.

Finally, the author would like readers to note that it is not possible to learn all the above assessment procedures by simply reading this paper. Some will require repeated hands-on training before the practitioner masters the technique. The bowstring test is a good example of this, as are the techniques of palpation of back and hip girdle trigger points.

Acknowledgement

The author is very grateful to his colleagues Dr Sosie Kassab (left) and Dr Jenny Peacock (right) from the Royal London Homeopathic Hospital for their help and patience with the photographs.





This is a flow diagram of assessment, categorisation and management.

LBP: low back pain; ZAJ: zygapophyseal joint; SIJ: sacroiliac joint.

* this box represents the standard evidence-based advice for LBP. Acute or chronic may refer to patients in either category.

† the percentages in this box are very approximate estimates, which are in part based on the author's clinical audit, but mostly are an impression from clinical practice.

Reference list

1. Hayhoe S, Box H. A questionnaire on medical acupuncture practice. *Acupunct Med* 1997;15(2):96-9.
2. Speed C. Low back pain. *BMJ* 2004;328(7448):1119-21.
3. Bogduk N. *Clinical anatomy of the lumbar spine and sacrum*. 3rd ed. Edinburgh: Churchill Livingstone;1997.
4. Pain history sheet. Available from <http://www.medical-acupuncture.co.uk/clinic.shtml>
5. Cummings M. Piriformis Syndrome. *Acupunct Med* 2000;18(2):108-21.
6. Macleod J. *Clinical examination*. 5th ed. Edinburgh: Churchill Livingstone;1979.