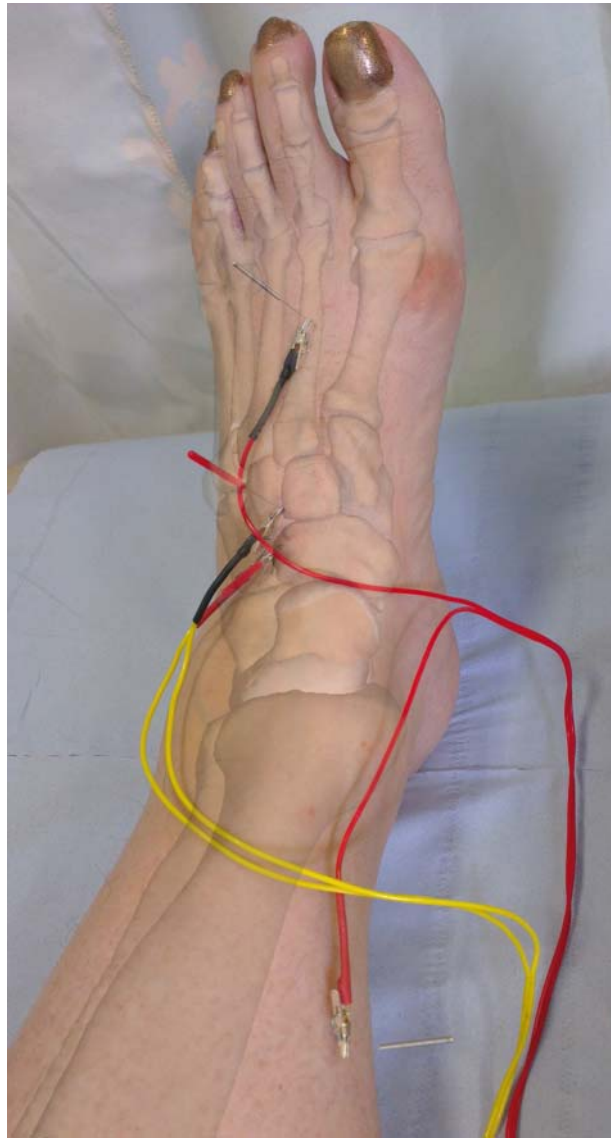


EA to the cunionavicular



This is a photograph of a test treatment for pain related to intermediate cuneonavicular osteoarthritis. A pair of needles is placed onto the tender proximal joint margin, and a further pair placed in regional acupuncture points SP6 and LR3. The superimposed image of the bones and joints of the ankle and foot is taken with permission from Primal Interactive Human: The 3D Real-time Body. The composite image was produced using Adobe Photoshop CS6.

Image and text kindly provided by Mike Cummings, Medical Director BMAS.

3D anatomy image copyright Primal Pictures. From *Primal Interactive Human* <http://www.primalpictures.com>